

The Case Report of A Patient with Relapses of B-cell Lymphoma in the Breast Parenchyma

Grebić, Damir; Valković Zujić, Petra; Trbojević, N

Source / Izvornik: **West Indian Medical Journal, 2015, 65, 209 - 211**

Journal article, Published version

Rad u časopisu, Objavljena verzija rada (izdavačev PDF)

<https://doi.org/10.7727/wimj.2014.190>

Permanent link / Trajna poveznica: <https://urn.nsk.hr/urn:nbn:hr:184:109036>

Rights / Prava: [Attribution 4.0 International](#)/[Imenovanje 4.0 međunarodna](#)

Download date / Datum preuzimanja: **2025-03-18**



Repository / Repozitorij:

[Repository of the University of Rijeka, Faculty of Medicine - FMRI Repository](#)



Case Report of Patient with Relapse of B-cell Lymphoma in the Breast Parenchyma

D Grebić¹, PV Zujic², N Trbojević³

ABSTRACT

We present a patient with relapse of B-cell non-Hodgkin's lymphoma in the breast that was clinically presented as a primary breast cancer. A 72-year old female was treated with chemotherapy and monoclonal antibodies (anti-CD20) due to diffuse large B-cell non-Hodgkin's lymphoma. Complete remission was achieved. Three years later, she was presented with a palpable left breast lump in the perimammillar area of the left breast, dimensions up to 3 cm. Laboratory results were within normal range. Mammography re-vealed a solitary, bilobulated, non-calcified mass of the left breast. On ultrasound, the lesion was hypo-echoic with blurred edges, with posterior acoustic enhancement, measuring 2 × 3 × 7 × 2 cm. Histological findings of ultrasound-guided fine needle aspiration and core needle biopsy were corre-spondent to diffuse large B-cell lymphoma. Pathohistological report showed cells with CD20+/Bcl- 2+/Bcl-6-/MUM-1+/CD3- imunophenotype. The breast parenchyma was infiltrated with B-cell lym-phoma. After diagnosis was confirmed, radiotherapy was initiated. Repeat ultrasound studies showed complete regression of the left breast lesion as did positron emission tomography-computed tomography (PET/CT) scan three months after therapy. In conclusion, the relapse of lymphoma in the breast is very rare. In patients previously treated for lymphoma, differential diagnosis should always include relapse, although it clinically presents itself as a primary breast cancer.

Keywords: Breast, non-Hodgkin's lymphoma, relapse

Reporte de Caso de una Paciente con Recaída de Linfoma de Células B en el Parénquima Mamario

D Grebić¹, PV Zujic², N Trbojević³

RESUMEN

Presentamos un paciente con recaída de linfoma de células B no Hodgkin en el pecho que fue clínicamente presentado como cáncer de mama primario. Una mujer de setenta y dos años fue tratada con anticuerpos de quimioterapia y monoclonales (anti-CD20) debido a la extensión de grandes células B linfoma no Hodgkin. La enfermedad se curó. Tres años después, el paciente se presentó con un bulto palpable en el pecho izquierdo. Chequeo reveló la formación palpable en la zona perimammilar del pecho izquierdo, dimensiones de hasta 3 cm. Los resultados laboratóricos estaban dentro de los límites normales. La mamografía reveló masa solitaria, extendida, no calcificada del pecho izquierdo. En la ecografía la lesión fue hipoecoica con bordes borrosos, con realce acústico posterior; midiendo 2 × 3, 7 × 2 cm. Los hallazgos de la ecografía, un aspiración con aguja fina guiada con ultrasonido y la biopsia de aguja gruesa correspondiente a linfoma difuso de células B grandes. El informe histopatológico mostró células con CD20+/Bcl-2+/Bcl-6-/MUM-1+/CD3- inmunofenotipo. Los resultados indicaron la infiltración del parénquima del pecho con el linfoma de células B. Al confirmar el diagnóstico, se inició la radioterapia. La ecografía mostró una regresión completa de la lesión del seno izquierdo. El tomografía por emisión de positrones/tomografía computarizada (TEP/TC) realizado tres meses después de la terapia confirmó la remisión completa de la enfermedad. En conclusión, la recaída del linfoma en el pecho es muy extraña. En los pacientes con linfomas tratados previamente, el diagnóstico diferencial debe incluir siempre una recaída aunque se presenta como un cáncer de mama primario.

From: ¹Department of Surgery, ²Department of Radiology, Clinical Hospital Center Rijeka, School of Medicine, University of Rijeka, Krešimirova 42, 51000 Rijeka, Croatia and ³Medical Faculty of Rijeka, School of Medicine, University of Rijeka, Braće Branchetta 20, 51000 Rijeka, Croatia.

Correspondence: Dr D Grebić, Department of Surgery, Clinical Hospital Center Rijeka, Krešimirova 42, 51000 Rijeka, Croatia. E-mail: damir.grebic@medri.uniri.hr

Palabras clave: Pecho, linfoma no Hodgkin, recaída

West Indian Med J 2016; 65 (1): 210

INTRODUCTION

B-cell lymphomas are a heterogeneous group of diseases that are caused by malignant proliferation of precursor or mature B lymphocytes (1). Diffuse large B-cell lymphoma (DLBCL) represents 30% of all non-Hodgkin's lymphomas [NHL] (2). About one-third of all lymphomas occur in extranodal structures (3). However, the breast comprises only 2% of localized extranodal NHL presentations (4).

We present a 72-year old female patient with relapse of B-cell lymphoma in the breast that was clinically presented as primary breast cancer.

CASE REPORT

A 72-year old female was treated with chemotherapy (R-CHOP protocol – rituximab-cyclophosphamide, doxorubicin, vincristine and prednisone) and monoclonal antibodies (anti-CD20) due to diffuse large B-cell non-Hodgkin's lymphoma. Complete remission was achieved, which was confirmed by positron emission tomography–computed tomography (PET/CT) scan. Three years later, the patient presented with a lump in the left breast (Fig. 1).

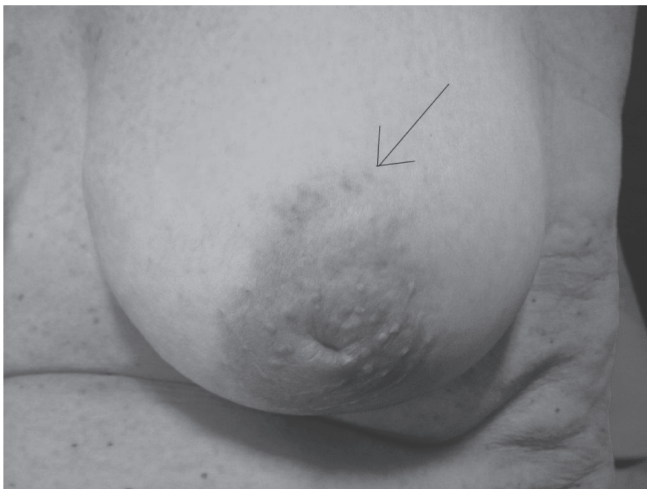

Fig. 1: Photograph of the left breast. Arrow indicates breast lump.

Physical examination revealed palpable formation of the breast in the perimammilar area at the border of the lateral quadrants. On palpation, the lesion was hard, fixed and motionless to the ground, dimensions up to 3 cm with impression of an infiltrative growth. Clinical examination of the supraclavicular and axillary region was unremarkable, without lymphadenopathy. Laboratory results and tumour markers were within normal range. Positron emission tomography–computed tomography scan showed suspected changes only in the left breast, which corresponded with mammographic finding of a bilobular, non-calcified mass located in the retromammilar

area of the left breast. The lesion borders on mammography were partially obscured due to superimposition by surrounding parenchyma (Fig. 2).

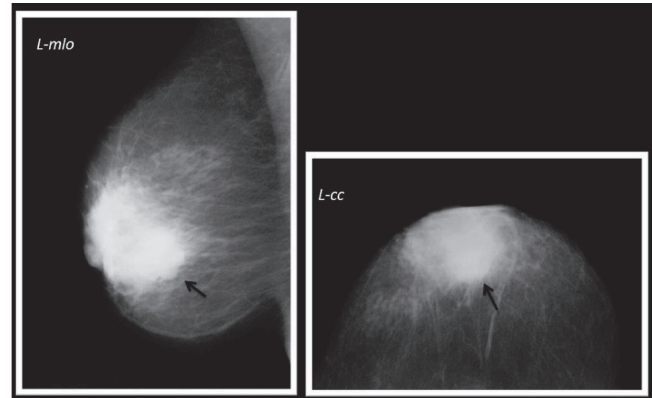


Fig. 2: Mammogram of the left breast in mediolateral oblique and craniocaudal projection. Arrows point to posterior border of retroareolar bilobulated mass lesion. Ventral borders are superimposed by surrounding breast parenchyma.

Mammography was classified as BI-RADS 0 (Breast Imaging-Reporting and Data System). In order to better characterize the lesion, ultrasound was performed. Ultrasound finding corresponded to lobular hypoechoic lesion with blurred edges and posterior acoustic enhancement, measuring 2 × 3, 7 × 2 cm (Fig. 3). On colour Doppler image, peripheral vessels indicated prominent lesion vascularization (Fig. 4).

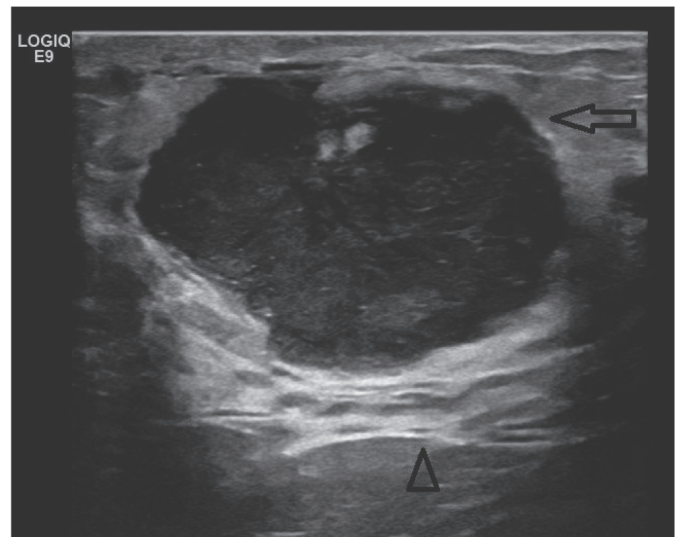


Fig. 3: An ultrasound image of the left breast. Arrow indicates the hypoechoic lesion with posterior acoustic enhancement (arrowhead).

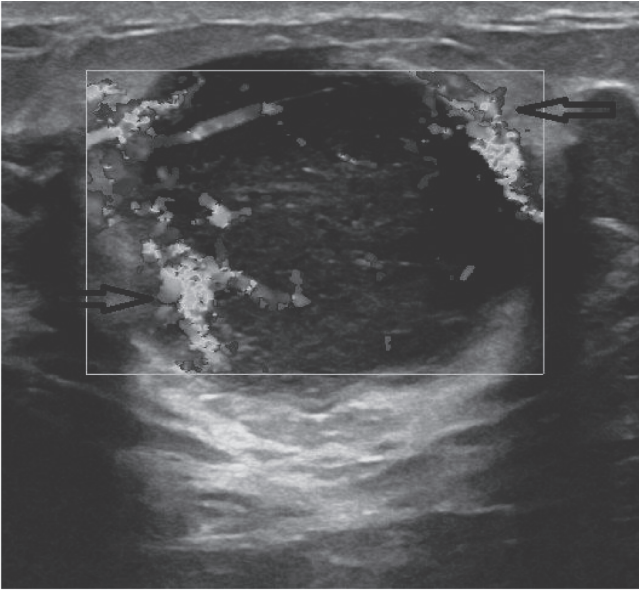


Fig. 4: Ultrasound colour Doppler image of the lesion in the left breast with prominent perinodal vessels (arrows).

Ultrasound-guided fine needle aspiration (FNA) was performed. Findings were morphologically correspondent with DLBCL so the search had to be supplemented with biopsy. Therefore, we performed ultrasound-guided core needle biopsy (CNB). Biopsy specimen showed tumour cells with CD20+/Bcl-2+/Bcl-6-/MUM-1+/CD3- immunophenotype. Findings corresponded to infiltrate of NHL of peripheral lymphocytes (CD20+), a form of DLBCL. After the diagnosis was confirmed, localized radiotherapy of the left breast was carried out with total dosage of 46 Gy. The repeat ultrasound and a PET/CT scan three months after therapy showed complete resolution of the lesion in the left breast. The patient achieved complete remission with radiotherapy.

DISCUSSION

We presented the case of a patient with relapsed DLBCL in the breast parenchyma. Three years previously, the patient successfully went into remission after treatment of NHL.

Occurrence of lymphoma in the breast is rare. More frequently, lymphoma occurs in the gastrointestinal tract, head and neck, skin and soft tissues. Location of lymphoma in particular sites can be an important prognostic factor. It is known that patients with extranodal involvement have poorer prognosis compared with nodal sites, especially if lymphoma affects the gastrointestinal tract, lungs, liver, pancreas or breast (5). Duration of remission also affects survival. Most patients relapse within two to three years. Patients with an aggressive form of lymphoma often have advanced disease stage at the time of diagnosis and recurrences are common, often within three years. Nevertheless, relapse of the disease can occur in the indolent form of the disease as well as early after obtaining

the diagnosis (6). The addition of rituximab to standard CHOP chemotherapy improved the prognosis of patients with DLBCL. The R-CHOP regimen contributes to prolonged survival and increases the number of patients with a complete response to therapy. The number of patients refractory to therapy is also reduced and so is the number of patients with relapse (7). The index patient had a relapse, although she was treated with rituximab in combination with CHOP protocol. This can be expected because DLBCL is a type of lymphoma with a very high rate of relapse. In 60% of cases, patients have an inadequate response to therapy or relapse (8). Despite the treatment with R-CHOP, this patient developed a relapse. It is important to note that relapses of DLBCL in most cases occur in solitary extranodal sites, as was the case with the index patient. As mentioned earlier, patients with extranodal relapses have poorer prognosis. Occurrence of multifocal relapse is very rare and is associated with chromosomal disorders (9).

In conclusion, lymphoma of the breast is rare, either as a primary or a secondary neoplasm. Nevertheless, in patients previously treated for lymphoma, with focal or multifocal changes in the breast, differential diagnosis should always consider relapse or metastatic process, despite the clinical presentation of a primary breast cancer. This condition is rare, but it is important to keep it in mind and take it into consideration before the final diagnosis.

REFERENCES

- López-Guillermo A, Colomo L, Jiménez M, Bosch F, Villamor N, Arenillas L et al. Diffuse large B-cell lymphoma: clinical and biological characterization and outcome according to the nodal or extranodal primary origin. *J Clin Oncol* 2005; **23**: 2797–804.
- Chao MP. Treatment challenges in the management of relapsed or refractory non-Hodgkin's lymphoma – novel and emerging therapies. *Cancer Manag Res* 2013; **5**: 251–69.
- Zucca E, Roggero E, Bertonni F, Conconi A, Cavalli F. Primary extranodal non-Hodgkin's lymphomas. Part 2: head and neck, central nervous system and other less common sites. *Ann Oncol* 1999; **10**: 1023–33.
- Aviv A, Tadmor T, Polliack A. Primary diffuse large B-cell lymphoma of the breast: looking at pathogenesis, clinical issues and therapeutic options. *Ann Oncol* 2013; **24**: 2236–44.
- Castillo JJ, Winer ES, Olszewski AJ. Sites of extranodal involvement are prognostic in patients with diffuse large B-cell lymphoma in the rituximab era: an analysis of the surveillance, epidemiology and end results database. *Am J Hematol* 2014; **89**: 310–4.
- Larouche JF, Berger F, Chassagne-Clément C, French M, Callet-Bauchu E, Sebban C et al. Lymphoma recurrence 5 years or later following diffuse large B-cell lymphoma: clinical characteristics and outcome. *J Clin Oncol* 2010; **28**: 2094–100.
- Coiffier B, Thieblemont C, Van Den Neste E, Lepage G, Plantier I, Castaigne S et al. Long-term outcome of patients in the LNH-98.5 trial, the first randomized study comparing rituximab-CHOP to standard CHOP chemotherapy in DLBCL patients: a study by the Groupe d'Etudes des Lymphomes de l'Adulte. *Blood* 2010; **116**: 2040–5.
- Kewalramani T, Zelenetz AD, Nimer SD, Portlock C, Straus D, Noy A et al. Rituximab and ICE as second-line therapy before autologous stem cell transplantation for relapsed or primary refractory diffuse large B-cell lymphoma. *Blood* 2004; **103**: 3684–8.
- Cabuk D, Gullu YT, Basyigit I, Acikgoz O, Uygun K, Yildiz K et al. Multifocal extranodal involvement of diffuse large B-cell lymphoma. *Case Rep Pulmonol* 2013; **2013**: 794642.