

Fatal Outcome of Emphysematous Gastritis due to *Sarcina ventriculi* Infection

Savić Vuković, Anita; Jonjić, Nives; Bosak Veršić, Ana; Kovač, Dražen; Radman, Marko

Source / Izvornik: **Case Reports in Gastroenterology, 2021, 15, 933 - 938**

Journal article, Published version

Rad u časopisu, Objavljena verzija rada (izdavačev PDF)

<https://doi.org/10.1159/000518305>

Permanent link / Trajna poveznica: <https://urn.nsk.hr/urn:nbn:hr:184:910432>

Rights / Prava: [Attribution-NonCommercial 4.0 International/Imenovanje-Nekomercijalno 4.0 međunarodna](#)

Download date / Datum preuzimanja: **2025-03-28**



Repository / Repozitorij:

[Repository of the University of Rijeka, Faculty of Medicine - FMRI Repository](#)



Single Case

Fatal Outcome of Emphysematous Gastritis due to *Sarcina ventriculi* Infection

Anita Savić Vuković^a Nives Jonjić^a Ana Bosak Veršić^b Dražen Kovač^a
Marko Radman^b

^aDepartment of Pathology and Cytology, Clinical Hospital Center Rijeka, Rijeka, Croatia;

^bDepartment of Pediatric Surgery, Clinical Hospital Center Rijeka, Rijeka, Croatia

Keywords

Gastroparesis · Emphysematous gastritis · Delay gastric emptying

Abstract

Sarcina ventriculi is an increasingly common bacterium with a variable pathogenic role. It is often an incidental finding in asymptomatic patients but can also lead to life-threatening conditions, such as gastric perforation and emphysematous gastritis. We report a case of a 14-year-old boy with fatal emphysematous gastritis caused by *S. ventriculi*, who presented with abdominal pain and vomiting. His medical history included infantile left hemiparesis and operation of patent ductus arteriosus. Emergency surgery was scheduled due to the extremely dilated stomach and gastric pneumatosis, and a total gastrectomy was performed. On the third postoperative day, he suddenly dies, and the diagnosis was confirmed postmortem. This case is an opportunity to review the clinical presentation of emphysematous gastritis and to point out the role of the histopathological examination for the identification of the bacteria.

© 2021 The Author(s).

Published by S. Karger AG, Basel

Introduction

Sarcina ventriculi is a Gram-positive anaerobic coccus that can grow in acidic environments, even in low pH of the stomach [1], with a carbohydrate fermentative metabolism as its sole energy source [2]. *S. ventriculi* is identified by light microscopy in gastric biopsy specimens with features of basophilic staining, cuboidal shape, tetrad morphology, and refractile nature [3].

It has been reported in the feces of healthy humans, particularly those with vegetarian diets. The organisms can normally be found in the soil and air and can survive for years by forming spores at alkaline pH [1].

S. ventriculi was first identified as a human pathogen by Goodsir [4]. Most patients present with gastrointestinal symptoms, such as nausea, vomiting, and/or abdominal pain [5], with some cases of severe disease, including emphysematous gastritis and gastric perforation [6–8]. Endoscopic findings often involve retained food residue, gastric ulcers, and inflammation or erosions [3]. Emphysematous gastritis is a rare and usually lethal gastrointestinal emergency, with an estimated mortality rate approaching 60% [9]. Here, we present a case of fatal emphysematous gastritis in a 14-year-old boy.

Case Report

A 14-year-old boy presented to the pediatric emergency department with a 3-day history of profuse vomiting and 1-day history of severe abdominal pain. He showed signs of dehydration with concerning vital signs: SpO₂ – 98%, pulse rate 108/min, and BP 86/49 mm Hg. His abdomen was distended and tender on palpation. Initial blood analysis showed elevated leukocytes ($31.8 \times 10^9/L$, 84.6 rel% granulocytes), urea (7.8 mmol/L), creatinine (109 $\mu\text{mol/L}$), bilirubin (109 $\mu\text{mol/L}$), alpha-amylase (132 U/L), lipase (496 U/L), and CRP (35.7 mg/L). His medical history included infantile left hemiparesis and operation of patent ductus arteriosus. Abdominal ultrasound was inadequate due to meteorism. A plain radiography of the abdomen showed an extremely dilated stomach, extending into the pelvis. Emergency CT scan confirmed the finding and reported gastric pneumatosis (shown in Fig. 1). Vascular structures and the entire bowel were compromised by the distended stomach. The liver structure was heterogeneous, and air was detected in portal veins as well. Free abdominal fluid was noted. The patient was admitted to the pediatric surgery ward. A nasogastric tube was placed, and 2.5 L of dark, frothy liquid was drained. His vital signs were unstable, and he was transferred to the intensive care unit. Emergency surgery was scheduled. Initially, laparoscopy was performed, which showed a dark-tinted,

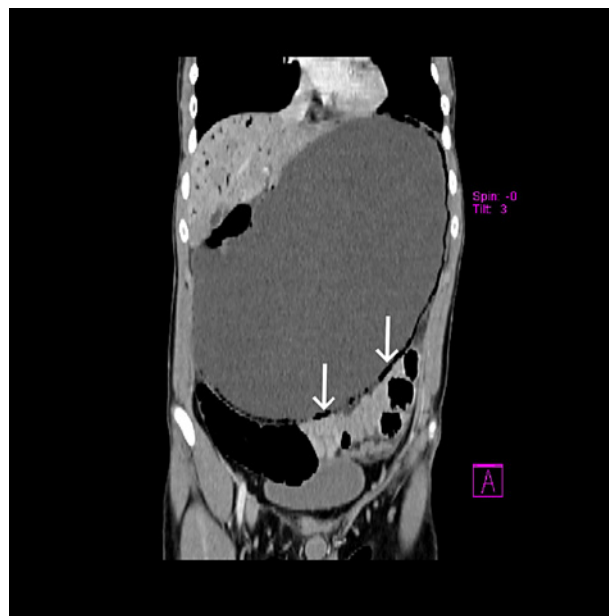


Fig. 1. Coronal plane CT reconstruction: gastric dilatation is seen along with pneumatosis (arrows).

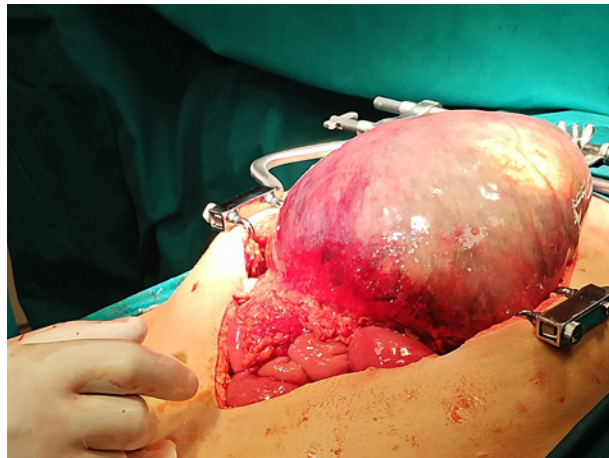


Fig. 2. Laparotomy view: extreme gastric dilatation.

distended stomach. The operation was converted to laparotomy. Before conversion, gastroscopy showed normal mucosa of the esophagus and dark, necrotic wall of the stomach. Over the whole operating field dominated a distinctly dilated stomach with necrotic wall and palpable crepitations as part of gastric pneumatosis (shown in Fig. 2). Inspection of the distal bowel did not show a clear cause of obstruction, so the stomach dilatation was interpreted as idiopathic. It is important to point out that the finding suggested chronic dilatation with a peracute stop of bowel content which led to compression and gangrene, rather than an acutely occurred dilatation. A total gastrectomy was performed with esophagojejunal anastomosis. The stomach was sent for histopathological examination.

Postoperatively, still analgosedated and intubated, he was transferred to the pediatric IC unit. His hemodynamic parameters were stable, with oliguria. Furosemide was administered. Ultrasound of the thorax showed a left pleural effusion that did not need invasive treatment. Control laboratory results showed a decrease in leukocytes $15.7 \times 10^9/L$ but a significant increase in CRP (320.8 mg/L). His coagulation tests were abnormal, so pooled human plasma was ordered. On the third postoperative day with his vital signs stable, he slowly regained consciousness and after a few hours was breathing spontaneously. After prior administration of dexamethasone, he was extubated and his response was stable. Control blood gas analysis was normal. Suddenly, he became restless, dyspnoic, and his oxygen saturation was decreasing. He abruptly fell into cardiopulmonary arrest. An immediate resuscitation protocol was carried out, with no ROSC outcome. The body was referred for an autopsy.

Due to the time required for analysis, the histopathological report of the stomach was complete after death. Histology showed full thickness necrosis with moderate neutrophil infiltration throughout all layers and hemorrhagic areas (shown in Fig. 3a). Air sacs were present in the mucosa and submucosa, suggestive of emphysematous gastritis (shown in Fig. 3b). There was abundant bacterial overgrowth, cuboid-shaped organisms arranged in distinctive basophile tetrad packets (shown in Fig. 3c). The bacteria were highlighted by strong positivity in Gram special stain. The final diagnosis of infection with *S. ventriculi* was established based on the characteristic morphology of these microorganisms and strong Gram positivity. The autopsy revealed multiple thrombi in the small blood vessels of the lungs and brain, with intra-alveolar hemorrhage and hemorrhagic necrosis of the liver and acute tubular necrosis. All this points to multi-organ failure and the development of disseminated intravascular coagulation. Areas of disturbed architecture were seen in the periventricular parts of the brain, with the demyelination of remaining neurons. Dystrophic calcifications were found in the surrounding areas. It was subsequently found heteroanamnestically that

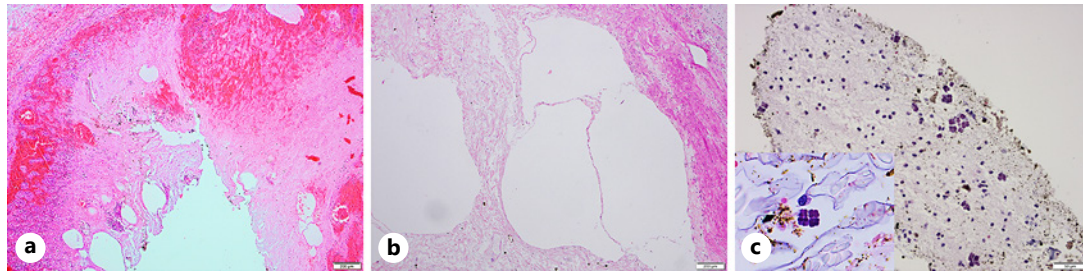


Fig. 3. Necrotic gastric mucosa and submucosa, with moderate neutrophil infiltration and hemorrhagic areas. **a** Hematoxylin and eosin, original magnification $\times 4$. Air sacs suggestive of emphysematous gastritis. **b** Hematoxylin and eosin, original magnification $\times 4$. Abundant bacterial overgrowth in the background of necrotic debris and retained food. Hematoxylin and eosin, original magnification $\times 20$. **Inset:** cuboid-shaped, basophilic organisms in a tetrad formation, characteristic morphology *S. ventriculi*. **c** Hematoxylin and eosin, original magnification $\times 60$.

these changes were due to transient hypoxia in infancy. The finding indicated periventricular leucomalacia.

Discussion

S. ventriculi, Gram-positive, anaerobic, spore-forming bacteria, which can grow in acidic environments was first identified by Goodsir [4], in a patient suffering from vomiting. It can be recognized by its characteristic morphologic features (basophilic staining, cuboidal shape, tetrad arrangement) [1]. It is seen predominantly in patients with delayed gastric emptying and has been associated with cases of gastric perforation and emphysematous gastritis [3].

In our case, there was delayed gastric emptying with gastric dilatation, probably as a consequence of gastroparesis. By definition, gastroparesis is a chronic heterogeneous motor disorder characterized by delayed gastric emptying without mechanical obstruction [9]. In children, the majority of cases are classified as idiopathic. According to the literature, other cases are related to infection, drug effect, complication of surgery (i.e., upper abdominal or lung and heart surgery) and as part of some diseases and conditions (i.e., cerebral palsy, prematurity, developmental delay) [10]. Our patient had cerebral palsy and operation of patent ductus arteriosus, which gives us 2 possible causes of gastroparesis. The delayed gastric emptying provides time for the organisms to grow and penetrate the gastric wall and produce gas [11]. Similar to ours, most patients present with non-specific symptoms, including abdominal pain, nausea, and vomiting. Emphysematous gastritis is very rare and a high level of knowledge is required for rapid diagnosis and treatment. The diagnosis is based on clinical, imaging, endoscopic, and histological findings. CT scan of the abdomen that demonstrates gastric intramural air with the acute abdomen symptoms is highly suspicious for the emphysematous gastritis [12]. The radiographic finding of portal vein gas represents the worst prognostic marker in these patients, with estimated mortality exceeding 75% [13].

Treatment should be started promptly and consists of intravenous antibiotics, analgesia, proton pump inhibitors, and total parenteral nutrition [12]. The role of surgery during the acute phase remains unclear, and indications for emergency surgery include clinical deterioration despite medical treatment, involvement of a large portion of or the entire stomach, and gastric infarction or perforation [14, 15]. In our case, surgery was scheduled due to the duration of symptoms, severe signs of shock that did not respond to proper medical treatment, and radiological signs suggesting possible gastric perforation.

Conclusion

S. ventriculi is an increasingly common bacterium with a variable pathogenic role. It has been identified in gastric biopsies from asymptomatic patients and without pathologic changes. However, it can cause nausea, dyspepsia, abdominal pain, gastric ulcer, rarely gastric perforation, and emphysematous gastritis with necrosis, which can be fatal, as in our case. Bacterial overgrowth was favored by delayed gastric emptying caused by gastroparesis. It is impossible to say whether the gastroparesis occurred due to cerebral palsy or heart surgery but led to delayed gastric emptying.

This case is a reminder to clinicians that abdominal pain, vomiting, and CT findings of air in the stomach wall and the portal vein may indicate emphysematous gastritis that requires prompt treatment to avoid mortality. It is also a reminder to pathologists of their key role in identifying bacteria in biopsies, to enable specific treatment.

Statement of Ethics

KBC Rijeka does not require ethical approval for reporting individual cases or case series. The paper was written with ethical considerations in accordance with the World Medical Association Declaration of Helsinki.

Informed Consent: Written informed consent was obtained from a legally authorized representative for anonymized patient information and any accompanying images to be published in this article.

Conflict of Interest Statement

The authors declare that there is no conflict of interest.

Funding Sources

This manuscript did not receive any funding.

Author Contributions

All authors certify that the patient has participated sufficiently in the intellectual content, concept, design, analysis, and writing. A. Savić Vuković diagnosed the patient, planned, wrote the manuscript and reviewed the literature. N. Jonjić and A. Bosak Veršić edited the manuscript. D. Kovač and M. Radman reviewed the manuscript. The final version of the manuscript was read and approved by all authors.

Data Availability Statement

All data generated or analyzed during this study are included in this article. Further inquiries can be directed to the corresponding author.

References

- 1 Lowe SE, Pankratz HS, Zeikus JG. Influence of pH extremes on sporulation and ultrastructure of *Sarcina ventriculi*. *J Bacteriol*. 1989;171(7):3775–81.
- 2 Claus D, Wilmanns H. Enrichment and selective isolation of *Sarcina maxima* Lindner. *Arch microbiol*. 1974;96(3):201–4.
- 3 Haroon Al Rasheed MR, Senseng CG. *Sarcina ventriculi*: review of the literature. *Arch Pathol Lab Med*. 2016;140(12):1441–5.
- 4 Goodsir J. XXIII: History of a case in which a fluid periodically ejected from the stomach contained vegetable organisms of an undescribed form. *Ann Mag Nat Hist*. 1843;11(68):125–6.
- 5 Lam-Himlin D, Tsiatis AC, Montgomery E, Pai RK, Brown JA, Razavi M, et al. *Sarcina* organisms in the gastrointestinal tract: a clinicopathologic and molecular study. *Am J Surg Pathol*. 2011;35(11):1700–5.
- 6 Laass MW, Pargac N, Fischer R, Bernhardt H, Knoke M, Henker J. Emphysematous gastritis caused by *Sarcina ventriculi*. *Gastrointest Endosc*. 2010;72:1101–3.
- 7 Tolentino LF, Kallichanda N, Javier B, Yoshimori R, French SW. A case report of gastric perforation and peritonitis associated with opportunistic infection by *Sarcina ventriculi*. *Lab Med*. 2003;34(7):535–7.
- 8 Dumitru A, Alius C, Nica AE, Antoniac I, Gheorghita D, Gradinaru S. Fatal outcome of gastric perforation due to the infection with *Sarcina* spp. A case report. *IDCases*. 2020;19:e00711.
- 9 Parkman HP, Hasler WL, Fisher RS. American Gastroenterological Association technical review on the diagnosis and treatment of gastroparesis. *Gastroenterology*. 2004;127:1592–622.
- 10 Wassem S, Islam S, Kahn G, Moshiree B, Talley NJ. Spectrum of gastroparesis in children. *J Pediatr Gastroenterol Nutr*. 2012;55:166–72.
- 11 Lam-Himlin D, Tsiatis AC, Montgomery E, Pai RK, Ahmad Brown J, Razavi M, et al. *Sarcina* organisms in the gastrointestinal tract: a clinic pathologic and molecular study. *Am J Surg Pathol*. 2011 Nov;35(11):1700–5.
- 12 Watson A, Bul V, Staudacher J, Carroll R, Yazici C. The predictors of mortality and secular changes in management strategies in emphysematous gastritis. *Clin Res Hepatol Gastroenterol*. 2017;41(1):e1–7.
- 13 Liebman PR, Patten MT, Manny J, Benfield JR, Hechtman HB. Hepatic-portal venous gas in adults: etiology, pathophysiology and clinical significance. *Ann Surg*. 1978 Mar;187(3):281–7.
- 14 Yalamanchili M, Cady W. Emphysematous gastritis in a hemodialysis patient. *South Med J*. 2003 Jan;96(1):84–8.
- 15 Jung JH, Choi HJ, Yoo J, Kang SJ, Lee KY. Emphysematous gastritis associated with invasive gastric mucormycosis: a case report. *J Korean Med Sci*. 2007 Oct;22(5):923–7.