

SHOULDER INSTABILITY

Olker, Niclas Georg

Master's thesis / Diplomski rad

2024

Degree Grantor / Ustanova koja je dodijelila akademski / stručni stupanj: **University of Rijeka, Faculty of Medicine / Sveučilište u Rijeci, Medicinski fakultet**

Permanent link / Trajna poveznica: <https://um.nsk.hr/um:nbn:hr:184:247541>

Rights / Prava: [In copyright](#)/[Zaštićeno autorskim pravom.](#)

Download date / Datum preuzimanja: **2025-03-17**



Repository / Repozitorij:

[Repository of the University of Rijeka, Faculty of Medicine - FMRI Repository](#)





MEDRI

**UNIVERSITY OF RIJEKA
FACULTY OF MEDICINE**

**INTEGRATED UNDERGRADUATE AND GRADUATE UNIVERSITY STUDY OF
MEDICINE IN ENGLISH**

Niclas Olker

Shoulder instability

GRADUATION THESIS

Rijeka, 2024



medri

**UNIVERSITY OF RIJEKA
FACULTY OF MEDICINE**

**INTEGRATED UNDERGRADUATE AND GRADUATE UNIVERSITY STUDY OF
MEDICINE IN ENGLISH**

Niclas Olker

Shoulder instability

GRADUATION THESIS

Rijeka, 2024

Thesis mentor: doc. dr. sc. Tomislav Prpić, dr. med

The graduation thesis was graded on 26.06.2024 in Rijeka before the Committee composed of the following members:

1 Izv. prof. dr. sc. Zdravko Jotanović, dr. med. (Committee Head)

2. Prof. dr. sc. Veljko Šantić, dr. med.

3. Nasl. izv. prof. dr. sc. Dalen Legović, dr. med.

The graduation thesis contains 30 pages, 4 figures, 0 tables, 29 references.

Thesis Table of Content

- 1. Introduction..... 1**
- 2. Aims and objectives 3**
- 3. Literature review about shoulder instability..... 4**
 - 3.1 Epidemiology of shoulder instability..... 4*
 - 3.2 Anatomy of the shoulder..... 4*
 - 3.3 General glenohumeral instability 6*
 - 3.3.1 Anterior instability 8*
 - 3.3.2 Posterior Instability..... 10*
 - 3.3.3 Multidirectional Instability 11*
 - 3.4 Diagnosis 12*
 - 3.4.1 Physical examination..... 12*
 - 3.4.2 Imaging methods..... 15*
 - 3.4.3 Special tests..... 16*
 - 3.5 Treatment options in shoulder instability 18**
 - 3.5.1 Conservative treatment 18*
 - 3.5.2 Surgical Treatment..... 21*
- 4. Discussion 24**
- 5. Conclusion 25**
- 6. Summary..... 26**
- 7. Literature..... 27**
- 8. Curriculum vitae..... 30**

List of abbreviations and acronyms

GH	Glenohumeral
AP	Antero-posterior
IGHL.....	Inferior glenohumeral ligament
MGHL	Middle glenohumeral ligament
SGHL.....	Superior glenohumeral ligament
AC.....	Acromioclavicular
SC	Sternoclavicular
MDI	Multidirectional instability
ST.....	Scapulothoracic
PNF	Proprioceptive neuromuscular facilitation
MRA	Magnetic resonance arthrography
MRI.....	Magnetic resonance imaging
NSAIDs	Nonsteroidal anti-inflammatory drugs
CT	Computed tomography
ROM	Range of motion
RC.....	Rotator cuff
HGAL	Humeral avulsion of glenohumeral ligament

1. Introduction

The instability of the glenohumeral joint is a prevalent condition in today's society, but mainly affects younger, individuals that are sportily active (1). An underlying causes for that are weakness or laxity in the structures stabilizing the joint, which can cause shoulder discomfort (2). Shoulder instability significantly affects patients' quality of life. Traumatic shoulder instability occurs in 1.7% of the population, with an 18% recurrence rate within the first year (3). Anterior dislocations account for 95% of cases, often requiring surgery due to Labral lesions. Multidirectional instabilities (MDI) of the shoulder are rare but significant, often linked to hypermobility conditions and a higher recurrence risk (3).

The shoulder is a joint composed out of many components. The complexity of this joint includes articulating bones, muscles, and connective tissue (4). The bony parts are made by the scapula, clavicle, humerus, Those bones are articulating with each other forming four minor joints: glenohumeral (GH), acromioclavicular (AC), sternoclavicular (SC), and scapulothoracic (ST) (4). The GH joint, a ball-and-socket joint, features a shallow glenoid cavity enhanced by the labrum. Muscles like the deltoid and rotator cuff, and nerves such as the axillary and suprascapular, are crucial for movement and stability (4).

Glenohumeral instability involves abnormal shoulder movement causing discomfort or dislocation (5). The Stanmore Instability Classification categorizes it into structural changes due to trauma and muscle imbalance (5). Types include traumatic structural, atraumatic structural, and atraumatic non-structural instability (5).

As mentioned above the anterior instability is more common, typically resulting from rapid injuries (3,5–8). Repeated dislocations often involve Bankart lesions and inferior glenohumeral ligament (IGHL) detachments (6). Posterior instability, though less common, can result from repetitive microtrauma or acute injuries (6). Diagnosis includes tests like the posterior drawer and jerk tests (5,6).

Physical examination for shoulder instability includes multiple observational and palpatory test, motion and force evaluations, and specialized tests like the anterior drawer and apprehension tests (1,4). Imaging methods such as X-rays, magnetic resonance imaging (MRI), and magnetic resonance (MR) arthrography are essential for detecting dislocations and soft tissue injuries (5,9,10).

Treatment options depend on the pathology. Non-operative rehabilitation focuses on proprioception, dynamic stability, and neuromuscular control (11). Surgical interventions, like

Bankart repair and capsular shift, are indicated for recurrent instabilities or specific needs of athletes. Despite advancements, complications and recurrence risks persist, requiring personalized treatment approaches (3)

2. Aims and objectives

This review study attempts to provide an overview of the illness of shoulder instability. The review's objectives include an epidemiological section that attempts to clarify the terminology of glenohumeral instability, including its prevalence, incidence, and risk factors; a summary of diagnostic options; and a discussion of treatment options for various types of instability, including conservative and surgical management. Overall, the purpose of this thesis on shoulder instability is to offer a comprehensive and current overview of this complicated issue, including diagnosis, therapy, and results.

3. Literature review about shoulder instability

3.1 Epidemiology of shoulder instability

Glenohumeral joint instability is widely spread phenomenon seen in orthopedic medicine patients. These instabilities can range from minor subluxations caused by hereditary causes to dislocations after trauma (11). Glenohumeral instability is defined as the inability to keep the humerus well placed in the glenoidal cavity, and it may be classified regarding to the origin and course of instability (6).

The majority, with around 95% of these instabilities appear to be anterior shoulder dislocations (5,7,8). Some incidences, like Traumatic dislocation with accompanied labral lesion frequently require operative treatment. The statistic occurrence of traumatic instabilities stated with up to 2% (7,12) in the general population, and more then 15% of affected people sustain from recurrent lack of stability within the initial year after dislocation (3).

Different types of shoulder instability, like MDI, are rare but significant for shoulder surgery specialists, peaking in the 20s and 30s. MDI can be seen in different syndromes which are accompanied hyperlaxity conditions. Patients that are identified as hypermobile do have a higher risk of frequent dislocation. The incidence of MDI with hyperlaxity in failed surgical procedures ranges from 61% to 100% (3). Even in absence of a hyperlaxity syndrome, MDI can occur, mainly followed by a trauma history, in very rare cases(3).

3.2 Anatomy of the shoulder

The anatomy of the shoulder is composed of various parts including skeletal components, stabilizing muscles, ligaments and nutrient providing nerves and vessels.

The shoulder anatomy is complex, with several bony components and ligaments required for proper function and stability. The triangular shaped scapula, makes one part and is located in the posterior part, has multiple muscle attachments. The glenoid anteriorly, makes up almost half of the glenohumeral joint. For the connection of the upper extremities to the skeleton, a transvers bone called clavicle articulates with the sternum towards the body's midline. The other crucial part of the glenohumeral joint is made by the humeral head (4). This proximal part that inserts into the shoulder joint (4) and forms a joint called glenohumeral (GH) joint.

This specific joint is named as ball-and-socket joint that connects the roundly shaped humeral head to the cup like surface of the scapula (the glenoid). Both articulating surfaces are coated with hyaline cartilage. The glenoid is an almost flat depression that is reinforced by a labrum (6), which stabilizes the joint and expands the articulating surface of the glenoid fossa immensely (4). The acromioclavicular (AC) joint, which connects the acromion (a scapular projection) with the clavicle, facilitates shoulder motion relatively. The sternoclavicular (SC) joint, which joins the clavicle to the sternum, is essential for shoulder movement. The scapulothoracic (ST) joint, which connects the scapula to the rib cage, helps to keep the shoulder flexible. The capsule's synovial membrane contributes to the production of synovial fluid, which lubricates and supplies nutrients to the joint (4).

The shoulder's ligaments are essential for its static stability (3). Therefore, duplication of the GH joints capsule is forming the GH ligaments. The superior GH ligament (SGHL), the middle GH ligament (MGHL) and the inferior GH ligament (IGHL) are limiting and preventing multidirectional translation of the shoulder during all kinds of movements (3,4). The coracohumeral ligaments connect the coracoid process to the humerus, limiting inferior and posterior translation. For the stabilization of the AC joint, acromioclavicular ligaments are the responsible agents which are supported by the coracoclavicular ligaments. The coracoacromial ligament prohibits displacement of the proximal humerus and is often involved in subacromial decompression treatments (4).

These components work together to ensure the glenohumeral range of motion (ROM) and solidness, making it vital for various arm and hand functions.(4)

The intricate network of muscle structure that sits atop the skeleton allows the shoulder to perform a variety of tasks. A complex network of muscles supports the shoulder, the most notable of which being the deltoid muscle. The axillary nerve innervates the deltoid muscle, which is responsible for the shoulder's shape and primarily acts to abduct the arm. It also promotes arm flexion and extension.(4)

Other important muscles include the teres major, which aids in inwards rotation and adduction of the arm, and the coracobrachialis, which works in both an adduction and flexion of the arm. The pectoralis minor, which originates in the ribs and inserts at the coracoid, works to depress the shoulder. The pectoralis major, which has a wide attachment along the humerus, is important for arm flexion, adduction, and internal rotation. The latissimus dorsi allows for arm extension, adduction, and internal rotation, whereas the trapezius stabilizes and rotates the scapula. The serratus anterior, which originates in the ribs, allows for shoulder abduction beyond 90 degrees

by displacing the scapula. The triceps muscle, which functions largely as an elbow extensor, also helps with arm adduction and retroversion (4).

The biceps brachii, which has two heads and originates from the coracoid and supraglenoid tubercle, is responsible for forearm supination and flexion, as well as arm flexion and adduction. The rotator cuff muscles are located above the shoulder capsule and is made up of the subscapularis, supraspinatus, infraspinatus, and teres minor muscles. This muscular compound works together to facilitate force coupling at the GH joint, which allows for shoulder mobility and stability. They are essential for maintaining dynamic stability (3,4) and alignment of the GH joint throughout the shoulder's ROM. The subscapularis is engaged in the humeral adduction and inward rotation, the supraspinatus in shoulder abduction, the infraspinatus in external rotation, and the teres minor in external rotation with the arm abducted (4).

The complex neural and vascular anatomy of the shoulder is among other structures composed of the brachial plexus, which splits into cords, branches, divisions, and roots from the C5-T1 nerve roots. Important to mention are the axillary nerve which main job is to innervate the deltoid and teres minor muscle and the suprascapular nerve, which innervates the supraspinatus and infraspinatus muscles (4).

The axillary artery serves as the principal vascular supply. This artery splits into several smaller ones and providing primary blood supply to the humeral head (4).

3.3 General glenohumeral instability

Due to the shoulders ability to move in an extraordinary wide range, which is unique in our body, this joint is losing a lot of its own stability. It's essential to recognize the distinction between joint laxity and instability. Joint laxity indicates that the shoulder joint can move within a typical range without generating issues or discomfort. In contrast, joint instability refers to abnormal shoulder mobility that causes symptoms such as discomfort, partial dislocation (subluxation), or full dislocation. (5) The causes and classification of shoulder instability are complex, but a widely acknowledged approach known as the Stanmore Instability Classification can help you understand and manage this issue. At the Royal National Orthopedic Hospital a categorization system was primarily established and it divides shoulder instability into two categories: (5)

1. Structural Changes: These occur because of severe trauma (e.g., dislocation, or repeated minor injuries)

2. Muscle Imbalance: This is characterized by incorrect muscle activation, causing the humerus head displacement from the glenoid

From a clinical perspective, shoulder instability might be separated into three main subtypes:

Type I: Traumatic Structural Instability: Instability caused by significant trauma (5)

Type II: Atraumatic (or Minimally Traumatic) Structural Instability: Instability with little or no trauma (5)

Type III: Atraumatic Non-Structural Instability (Muscular Dyskinesia): Instability due to improper muscle coordination (5).

These categories establish a triangle relationship (see Figure 1), recognizing that many patients' symptoms may fall within these types or transition from one category to another over time.

For example, if a structural problem is not addressed, it may later rise to muscular coordination difficulties, complicating the illness. However, muscle patterning issues can eventually lead to structural defects. This classification helps to realize that shoulder instability is frequently caused by a mix of structural and muscle abnormalities that can develop over time (5).

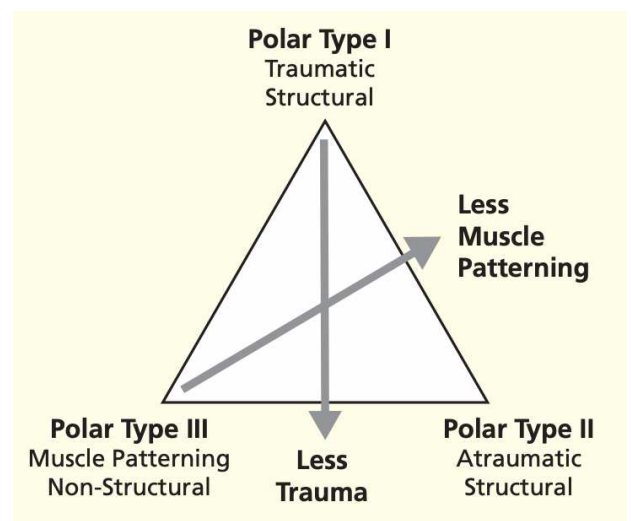


Figure 1.: Stanmore instability classification (5)

A dislocation happens when the shoulder joint surfaces entirely separate, whereas a subluxation is a partial separation that produces symptoms but does not result in a complete dislocation (5). As already mentioned above the Glenohumeral instability can be described as the inability to maintain the humerus concentrically within the glenoid cavity, and it may be classified according to the origin and direction of instability (6).

Dislocations may be classed as voluntary, dynamic, or static. Static decentering of the humeral head results from major structural abnormalities like glenoid dysplasia or severe rotator cuff

injuries. The typical type of dynamic instability, which is frequently brought on by trauma, is linked to glenohumeral ligament tears, labrum injuries, and glenoid rim fractures. It can also result in generalized hyperlaxity (6).

Instability can be in one direction (anterior or posterior) or in multiple directions (MDI), second-mentioned affecting a fewer number (6). Unidirectional instability may occur after a single bigger trauma or can follow after many minimal energetic instability traumata, whereas the majority presents as anterior instability (7). The criteria for diagnosing MDI remain debatable due to the lack of a clear definition. MDI primarily was defined by Neer and Foster 'as anterior and posterior instability along with involuntary inferior subluxation or dislocation' (7,13). Different writers described MDI as the lack of stability in more than two dimensions (14). Imaging requires the separation of instability into traumatic and atraumatic categories. Traumatic instability frequently manifests as bony, ligamentous, and labral lesions, but atraumatic instability may not (6).

The labrum, ligaments, and bony components promote the stability of the shoulder joint. Upon radiographical studies the labrum is one of the most focused areas on, even though it only accounts for 10% of the joint's stability, highlighting the importance of thoroughly evaluating the ligaments and bony structures as well (6).

3.3.1 Anterior instability

The anterior instability (see Figure 2) is the most prevalent type of instability with around 95%. (3,5,7,8). Anterior shoulder instability is generally caused by a rapid injury that forces the arm is simultaneously abducted, whilst externally rotated, and extended. This type of injury is categorized as Polar type I (5,15). This can result in repeated dislocations, when the labrum and capsule detach from the front of the shoulder socket, a condition known as a Bankart lesion (5,6).

The inferior glenohumeral ligament (IGHL) is responsible for shoulder stability by linking the glenoid to the humerus and therefore represents the most important stabilizer in this joint (6). It usually attaches to the labrum as well as some fibers to the glenoidal neck in 80% of the cases, or solely to the glenoid neck 20% of the cases (6).

Detachment of the labrum typically results in detachment of the IGHL (6).

Failures are most common on the glenoid side, but when they occur on the humerus side, they are namely called humeral avulsion of Glenohumeral Ligament (HAGL) lesions (11).

Arthroscopy can make it difficult to diagnose HAGL defects. Whereas arthrographically, indicators include the J sign and axillary fluid leaking, however false positives are common (6). For clinical features the most frequent patients are young men or women who report the shoulder 'coming out', mostly whilst being physically active (5).

Initial incidents of a dislocation can be used as a clinical marker, and the patient might be able to precisely explain the course of events: a forceful impact with the shoulder abducted, externally rotated, and extended. X-rays may have confirmed the diagnosis, and the injury might be treated for many weeks depending on the extent (5).

Bony lesions are also prone to appear in traumatic occurrences. These can be either glenoidal or humeral lesion mainly seen in an MRI examination (6).

Bony involvements within the glenoid rim can be critical for an unstable glenohumeral joint, especially if it exceeds half of the glenoid's AP diameter, as it significantly reduces dislocation resistance. Such defects often require a Latarjet or bone grafting procedure. Glenoidal bone impairments can be congenital, result from a fracture, or develop from chronic instability, causing glenoid bone loss (6,7).

A very common lesion in dislocations is the Hill-Sachs lesion. It is a dent in the back of the proximal humerus, created due to it colliding with the front of the socket during dislocations, is also possible (5–7).

The shoulder may partially dislocate (subluxation) rather than totally dislocate, in which case the labral rupture or fracture may not be visible, but the inferior glenohumeral ligament may have stretched. Shoulder dislocations in people over 50 are frequently associated with rotator cuff injuries (6).

The second group of shoulder instabilities are atraumatic or minimal traumatic and can involve conditions like 'loose shoulder' or voluntary and habitual dislocations. These entities can be subdivided into structural and non-structural etiologies (5). And can be considered as Group Polar II and III (3,5,15).

Atraumatic structural instability is a type of shoulder instability that develops over time because of repeated micro-trauma or quick, forceful movements, resulting in joint laxity. Glenoidal dysplasia as a predisposing condition may exist sometimes in these patients. Atraumatic structural instability is common in sportsmen, particularly swimmers and throwers, who have symptoms owing to stress and fatigue in the shoulder's stabilizing muscles, which can result in dislocation in many directions. It is critical to exclude any pathological diseases, such as labral lesions, and to determine whether aberrant muscle patterns contribute to the instability (5).

On the other hand, the atraumatic non-structural instability, also known as altered muscle structuring, occurs when the shoulder's stability is compromised due to disrupted coordination of muscle contractions and relaxations. This instability often affects younger individuals who can voluntarily dislocate their shoulder as a trick, but it may lead to repeated involuntary dislocations (5).

A phenomenon belonging to this group of instabilities is Inferior subluxation. This event occurs weeks after a shoulder injury, causing a feeling of instability, especially when carrying heavy objects. An X-ray may show the humeral head subluxated downward. If not apparent, further X-rays with the patient holding 10 kg weights can confirm it. This condition results from temporary shoulder muscle weakness due to prolonged immobility and lack of exercise. It usually resolves with normal muscle activity, but physiotherapy can accelerate recovery. In persistent cases, surgical tightening of the capsule (capsular reefing) may be necessary (5).

3.3.2 Posterior Instability

One of the most common Etiologies in posterior instability is due to repetitive microtrauma from physiological or pathological occurrences (5,6). This could be heavy training (weightlifting or pushups) (6) or due to epileptic jerk or electric shock (5). Anatomical determinant for posterior instability of the shoulder joint involves an extended retroversion of GH joint components, as well as posterior glenoid dysplasia, which can arise in conditions such as brachial plexus birth palsy (6).

Acute posterior glenohumeral dislocation is uncommon and often failed to see. During anamnesis the patient explains the accident mostly in the context of forceful injury whilst the arm is internally rotated, while external rotation is resisted. An anteroposterior X-ray may show a 'light bulb' phenomenon due to internal rotation of the humeral head (5). A radiography from the axillary angle can clearly show the dislocation if the arm is abducted. Recurrent posterior instability usually presents as subluxation during flexed and inwards rotated. Diagnosis is confirmed with the posterior drawer test and posterior apprehension test (5).

Shoulder Dislocation

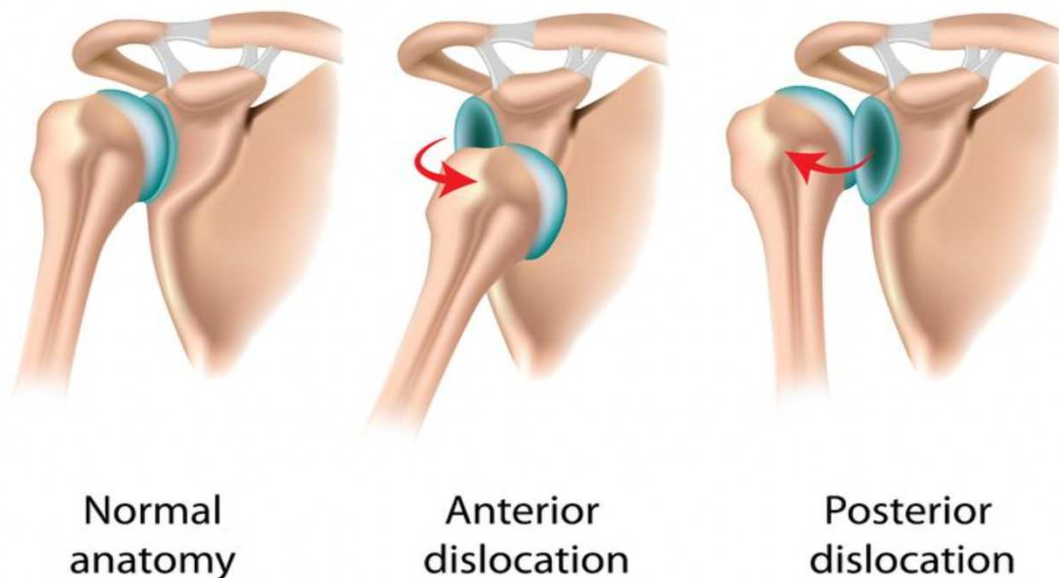


Figure 2.: Shoulder Dislocation (16)

3.3.3 Multidirectional Instability

A third and less distributed form of instability disorder is the multidirectional type (see Figure 3.). The development of this condition is not really known due to shortage of observations. And definitions are not really clear, sometimes including trauma as a factor and some do not include this (3,17). Though less common, this circumstance presents substantial challenges for shoulder specialists, especially in patients with hypermobility conditions (3). These patients show a higher risk of reoccurring dislocation and lack of stability, with surgical failures often linked to hyperlaxity (3). MDI patients is consider to present with unstable shoulder in at least two

directions (14,17), furthermore they can have a broad variety of symptoms regarding to different studies (17). As already mentioned, above the clinical picture could include an anterior and/or posterior lack of stability with signs of and subluxated joint (7,13). The optimal therapeutic approach needs to be variable and adjusted to the patients' needs. The huge variety of clinical presentation doesn't allow a clear definition, so each patient has a necessity to be treated for his/her signs and symptoms. Most of the treatment options to choose from are mainly surgically by capsule shifts or labrum repairs (17).

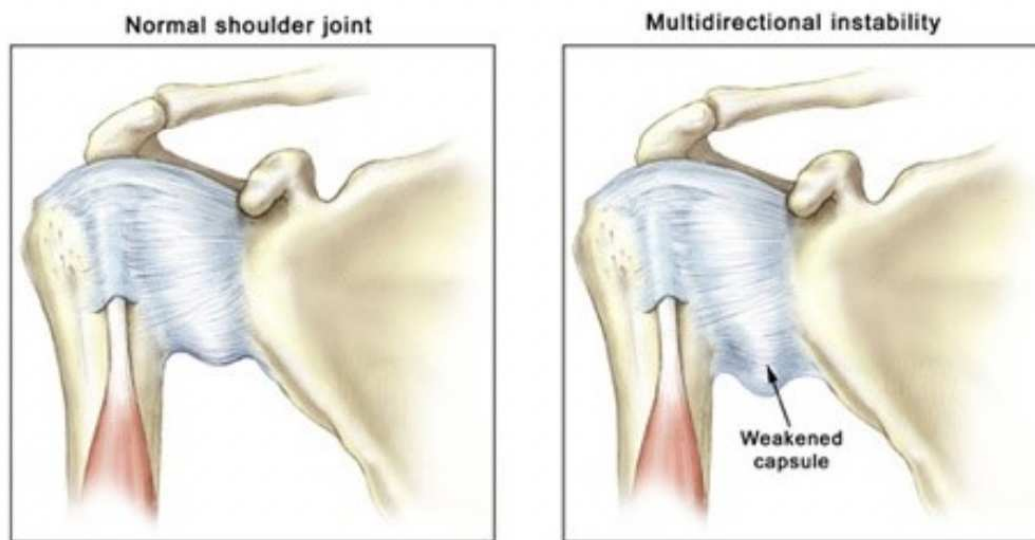


Figure 3.: Pathology of a multidirectional instability (18)

3.4 Diagnosis

3.4.1 Physical examination

Before we are starting with the general examination, we are taking a specific patient history. This will enable the examiner to be more focused and precise during the physical exam (1). Generally spoken the shoulder examination is composed of multiple observational and palpatory test, as well as specific tests for muscles and ligaments. Both shoulders should be exposed for comparison, starting with the healthy shoulder to establish a basic capacity (1). The physical exam of the shoulder should be done very precisely and considering all the possible issues that can cause problems in the region of the shoulder. Therefore, it could be useful to

begin the examination with a careful review of the cervical vertebrae. Unphysiological conditions in the cervical region can be the origin for pain in the upper extremity. The ROM is assessed across each dimension. Nerval involvements are judged by using the Spurling test, which involves extending and rotating the patient's neck towards the affected side, while performing axial compression (1).

External inspection can be a very good indicator for asymmetry in the shoulder due to muscular atrophy. This might indicate disorders such as axillary nerve palsy, rotator cuff rupture, or nerve entrapment. Deltoid atrophy can result in lateral shoulder squaring, whereas supraspinatus and infraspinatus atrophy may indicate rotator cuff problems or nerve entrapment. Furthermore, the scapula's posture should be checked for winging, and the skin examined for scars or scar widening, which may indicate a collagen issues (1,4).

The next step in the physical exam should be the palpation, where each joint around the shoulder is precisely examined. This step is crucial to detect areas of trauma, with sign of a fracture like crepitus or tender surfaces in the area of the shoulder (1,4).

An important key for the right diagnosis is the motion test of the shoulder. Shoulder motion testing should encompass all motions the shoulder is capable of. The examiner should precisely look for active and passive movements in all dimension like flexing forwardly, abduction, rotation (external and internal), and in abduction up to the right angle (1,4). Estimating the level of adduction whilst the arm is internally rotated is measured by someone's capacity of reaching specific landmarks on the vertebral column with his fingers. These landmarks are at the level of thoracic vertebra 4, the superior scapular border, at the thoracic vertebra 7, the inferior scapular border, and the fourth lumbar vertebra at the height of the iliac crest (1). A healthy shoulder should be able to flex forwardly in a range of 150-180 degrees, which is the same range of estimated abduction. In shoulder extension we expect a normal range between 40-60 degree while for the external rotation 60-90 degrees are considered to be normal. If the patient can bring the arm to the midthoracic level of 50-70 degrees, internal rotation is evenly assumed to be normal (4). While examining the shoulder the deprivation of one or multiple motions can suggest different pathologies. A reduced motion in combination of active and passive can indicate osteoarthritis of the shoulder, whereas a diminished active movement solely indicates potential damage to the rotator cuff muscles. This diagnostic test has to be seen in relative motion compared to the passive motion.(4)

All the bones belonging to the shoulder need to be examined as well. The scapula for example, plays a crucial role in shoulder movement, known as the "scapulohumeral rhythm" which is responsible for the last part of abduction (4).

In a shoulder examination, strength is evaluated by comparing the patient's strength to that of the contralateral limb. The Jobe, or "empty can" test is often used to evaluate supraspinatus tendon injury, which involves placing the arm to maximize stress on the tendon while noting pain or weakness (1,4). In the lateral Jobe test, a more sensitive version, force is applied downwards, and assesses supraspinatus damage by detecting discomfort or weakness (4). The drop arm test, however less specific, detects rotator cuff disease by controlled adduction. The infraspinatus tendon and teres minor is assessed in abduction using resisting outward rotation (1) A lag sign for one rotator cuff muscle, in this case the infraspinatus, is if the patient is not capable to keep the externally rotation position in the previous angle (1).

Furthermore, the teres minor intactness, is tested with the patient's arm is put in abduction passively and rotated externally up to the right angle. The inability to hold this position is the so called Hornblower sign. If the patient complains about pain while resisting in this position a tendinopathy or other minor lesions can be suspected (1,4).

Evenly important for a complete examination is the evaluation of the neurovascular status. A complete neurovascular evaluation is required perioperatively. The axillary nerve, which is usually affected in dislocations, is assessed by stressing the deltoid muscle with an abduction exercise and teres minor with outward rotation whilst the arm being abducted. Lateral shoulder sensation needs to be examined as well. Additionally, damage to the radial, median, ulnar, and musculocutaneous nerves should be evaluated even though there are not that prone to happen (1).

The vascular examination includes palpating the peripheral pulses, comparing capillary refills, as well as looking for temperature changes, skin changes, or hair loss. The Adson technique can be used to assess thoracic outlet syndrome, which is characterized by nonspecific pain or weakness. A reduced radial pulse following arm extension and head tilting indicates compression of the subclavian artery (1,4).

One of the last choice an examiner has are diagnostic injections. Diagnostic injections are useful for determining shoulder pathology when a history and physical examination do not provide enough information (1,4). Steroid injections, which are frequently paired with local anesthetics (4), help pinpoint the cause of pain by relieving symptoms when put into the proper area. Ultrasound or image guidance improves the precision of these injections. Specific injections, such as those into the AC joint, subacromial area, or biceps tendon sheath, aid in the diagnosis and treatment of bursitis, rotator cuff tears, impingement, AC joint pain, and biceps tendonitis (1,4). These injections can help guide clinical decisions and confirm diagnosis based on the patient's response to treatment.

3.4.2 Imaging methods

Further investigation and imaging can be necessary if the diagnosis of an instability and dislocation. An anteroposterior (AP) radiograph with the inwards rotated shoulder, or an axillary view, is ideal for detecting a Hill-Sachs lesion in an anterior instability/dislocation. Subluxation can be visible in this imaging as well (5). Plain x-ray can be a very important tool regarding conformation of an anterior shoulder dislocation. Therefore, clinically significant fractures happen in roughly every fourth patient with these dislocations. A study found multiple factors linked to this incident (9,19):

- Age exceeding 40,
- Primary dislocation,
- Traumatic mechanism (e.g., fight or fall).

When a glenohumeral dislocation is suspected, the best imaging views to obtain are an AP and a scapular "Y" view. If the diagnosis is not definite, an axillary view should be acquired. The AP view frequently shows an anterior shoulder dislocation, with the humeral head in a sub coracoid position. Larger degrees of dislocation, such as sub clavicular or sub glenoid locations, are frequently associated with injuries such lesions of the rotator cuff or larger tuberosity damage (9).

In case of an suspected posterior dislocation an AP view X-ray can mask a dislocation up to 50% (20). Clinical features to look at are lightbulb sign, rim sign, and trough line sign (9). The lightbulb sign occurs when the proximal humerus rotates inwardly and the tuberosities no longer protrude sideways, making the humeral head appear round (9). If two lines of cortical bone appear side to side on the medial side of the proximal humerus, we are talking about the trough line sign. The first line indicates the medial part of the cortical humerus, while the second visible demarcation represents the "trough" of a fracture. This impression fractures is also known as the "reverse Hill-Sachs lesion", visible on the anterior border of the humerus (20,21). Computed tomography (CT) is mostly not indicated for an acute anterior dislocation. For a better planning in case of surgery, CT could be considered as an imaginary option (9). Due to the bad recognition of posterior pathology in plain X-ray CT can be an useful guide in these cases (22).

Magnetic resonance imaging or MR arthrography is excellent for detecting bone diseases and lesions of the labrum, for which arthroscopy is occasionally required to diagnose more precisely

(5). MRI is ideal for evaluation of soft tissue injuries in the shoulder. MR arthrograms have higher specificity and sensitivity than standard MRI scans. Labral injuries, like a Bankart tear, or ligamentous lesion even impression fractures (like Hill-Sachs), can all be detected with MRIs (3,10).

Examination under anesthesia can aid in determining the direction of instability. This is an essential aspect in assessing instability, because muscular paralysis removes guarding and allows for a better knowledge of glenohumeral translation (1). Both shoulders should be evaluated. Reports have shown 100% sensitivity and 93% specificity (5).

3.4.3 Special tests

3.4.3.1 Evaluation of anterior instability

A complete evaluation for an anterior instability includes several tests to determine the stability and integrity of the glenohumeral (GH) labrum and adjacent components. The abilities are tested by quantitative and provocative test (1).

One test would be the anterior drawer test. This test requires the patients in a seated position with his arm being relaxed besides him. For this test force is applied from anterior while the practitioner fixates the scapula, while the other hand is isolating the humeral head. Increased motion in this test can be a relative indication for an unphysiological. In younger and sportily active patients, an increased ROM can be observed in the predominant side (1,4).

The apprehension test is performed either seated or lying on the rim of the examination couch, which helps to stabilize the scapula. The arm is abducted in a right angle, and the examiner progressively outwards rotates the GH Joint 90 degrees. An apprehensive impression or painful response in this position indicates lack of anterior stability or lesion to the labrum anteriorly. Enhancing for this test might be putting stress from posterior-to-anterior to the humeral head. Staying in this position, the relocation test can be performed apprehension test, delivering an opposite impact on the proximal humerus to reduce the patients discomfort and ache (1,4,5).

The load and shift test is used to analyze how much the upper arm (humeral head) shifts forward and backward in relation to the shoulder socket (glenoid), which is used to detect shoulder instability. Initially published in 1991 (4), the examiner steadies the shoulder blade and pushes the humeral head against the glenoidal cavity before checking for anterior and posterior shifting. Excessive movements suggest missing stability in that direction, with the test being less sensitive to posterior instability and virtually almost flawless specific in detecting an anterior instability. The examination is done with the patient sitting up or lying down, with the

shoulder softly abducted and flexed. The examiner holds the patient's upper forearm and uses an axial load to position the humeral head in the glenoid before applying forward-downward pressure (1,4).

The Gerber and Ganz or modified Hawkins categorization (see figure 4.) systems are used to assess translation based on the amount of humeral head movement relative to the glenoid edge, where both categorization divides shifting within 3 grades (1,23).





Grade	Diagrammatic	Clinical Feel
0 None		No translation
1 Mild		Humeral head moves slightly up face of glenoid (0-1 cm translation)
2 Moderate		Humeral head rides up glenoid face to but not over the rim (1-2 cm translation)
3 Severe		Humeral head rides up and over the glenoid rim <ul style="list-style-type: none"> • Usually reduces when stress removed • May remain dislocated when stress removed (rare) (>2 cm translation)

Figure 4: The Hawkins classification of instability (23)

3.4.3.2 Evaluation of posterior instability

Like the anterior instability, the posterior instability is equally assessed with analysis as the posterior drawer. The patient positioned in the same way with the affected arm to his/her side. The examiner stabilizes the scapula and pulls the proximal humerus backwards to determine the degree of shifting on the glenoid. Translation is defined as the fraction of the humeral head subluxated posteriorly, with up to 50% displacement considered normal (1,4). If the examiner recognizes movement over 50% this could be signs of subluxation or dislocation which would be a positive sign of instability (4).

The jerk test, also known as the Jahnke or posterior load test, is executed in supine position. The practitioner positions the patient's flexed arm in a right angle of, while being abducted completely. The examiner then delivers a rearwards force on the elbow with slight inwards rotation, (1).

3.4.3.3 Evaluation of multidirectional instability

A key point in the diagnosis and exam of an MDI is the determination of the instability of the GH joint in different dimensions. Exhausting tests are performed to see how the whole joint is acting towards that force. Some of these tests are already mentioned in the section above, like load and shift and apprehension test which can evenly be used for MDI inspection. The anterior and posterior laxity can be determined by the load and shift test and the apprehension test represents a more sensitive accessibility than just the patient's subjective feelings (24). A special test regarding the lower laxity is the so-called sulcus test (24). To perform the test, the examiner pulls the outstretched arm of the patient downwards. Small movements of the humeral head are considered to be normal, whereas felt movements above 2 cm can indicate a subluxation within the GH joint (2), forming a sulcus just below the acromion (24).

3.5 Treatment options in shoulder instability

Treatment options regarding shoulder instability are versatile and depend on the underlying pathology of the instability. Each case and patient need to be precisely examined and evaluated with the tests and methods mentioned above. Surgical repair is advised in the occurrence of structural destruction, as in Polar I group. The treatment has been proved to reassure shoulder stability (15,25). Patients associated with polar group III are most likely to have a muscular asymmetry. For those patients a conservative, muscle strengthening program could be more effective (15,26). Polar II treatment is contentious because this presentation frequently includes muscle patterning. The treatment options need to be evaluated carefully based on the specific results and histories from each patient. Further treatment options will be elaborated in the following (15).

3.5.1 Conservative treatment

For a non-operative (so-called conservative) rehabilitation the patients are separated into two groups of their instability etiology. These are either traumatic or atraumatic instabilities. Therefore traumatic unstable patients will follow a so-called 4-phase rehabilitation plan whereas atraumatic patients will mainly follow key principles during their rehabilitation program (11).

The first phase of the traumatic rehabilitation program, the acute phase, mainly focuses on reducing pain and protecting the vulnerable tissue and assuring the stability of the joint. Mobility restrictions vary regarding the age groups. Individuals below 29 years of age can start with an immediate controlled but restricted motion. Everyone above the age of 29 should stick to a strict immobilization (11). Gentle ROM exercises include pendulums, whip and Derries for shoulder blade plane elevation. ROM can be actively supported by using an L-bar for flexion and rotation within a non-painful arc (11).

Avoid pushing exercises while externally rotated for anterior instability, and excessive internal rotation in cases of low posterior stability (11).

Isometric exercises are improving the strength and depth perception involving the arm at the side, which can be enhanced by electrical muscle stimulation, and scapular exercises for retraction/protraction and elevation/depression. Rhythmic stabilization and weight shifts with closed kinetic chain exercises for anterior instability, along with deep perception training for rotation and flexion, can be performed (11,15).

To proceed to Phase 2, patients must have nearly full passive ROM (with some restrictions in outward rotation), low pain, improved manual muscle test, as well as dynamic stability to continue in that stage of recovery (11).

The intermediate phase focuses on regaining full range of motion and progressing through reinforcing exercises for the shoulder muscles, including rotator cuff (RC) and shoulder blade stabilizers. This phase requires reduced ache and inflammatory signs. The static stability should reach a satisfactory level and neuromuscular regulation should be adequately available (11).

Passive ROM exercises can be executed up to the patient's pain toleration. An achievable goal would be the almost full range of mobility without overstressing healing structures. Active-assisted ROM exercises with a pulley, as well as multidirectional exercises up to the right angle whilst abducted are gradually increased to tolerance (11).

The aim of Phase 3 is to enhance the shoulders stability and muscular power. The improvement of neuromuscular regulation should be clearly perceived. Gradual return to the patient's activities, particularly towards the end ROM, through incremental strengthening exercises is a crucial step here. Before continuing with this phase, the patient must have minimum ache and pressure sensitivity, a full ROM, and reinforced endurance in the muscles involved in stabilizing the shoulder and upper extremities (11). Exercise for endurance training can highly be repetitive in a lower reticence or timed between 30-60 seconds. These Activities, include rotational exercises and wall dribbling with a weighted ball (11).

Plyometric exercises are used to regain functional range of motion and increase neuromuscular control, which trains the extremities to handle forces. Initially, 2-handed workouts such as chest passes, and overhead throws with a medicine ball are utilized to improve dynamic stability. These activities begin near to the body center and eventually advance to further distances away from the body, testing the shoulder's dynamic stabilizers (11).

The goal of Phase 4 is to gradually increase the demands on the shoulder (functionally), allowing for a comeback to unrestrained sports and daily activities. Maintaining dynamic stabilization, shoulder reinforcement, and a broad ROM are essential milestones. To reach this phase, the patient must have completely mobility, appropriate stabilization, good muscle reinforcement and endurance, and a contenting clinical assessment (11).

Patients will follow a weekly program to improve strength and neuromuscular control, resulting in entire, painless range of motion. Athletes will perform advanced exercises such as plyometrics and isotonic strengthening before beginning specific sport practices as part of a progressive back to sport scheme. These programs are individualized to the individual's injuries, skill level, and objectives, with the goal of restoring motion and confidence while reducing the danger of re-injury (11).

In comparison to the posttraumatic rehabilitation, the atraumatic procedure looks less structured. Rehabilitation for patients with congenital shoulder instability is challenging due to frequent episodes of instability that limit daily, recreational, and sports activities. This instability often stems from factors like excessive capsular laxity, poor bone configuration, or muscle weakness, leading to poor neuromuscular control (11).

In atraumatic instabilities the approach during rehabilitation program focuses on a slower progression compared to traumatic instability, avoiding overly extending the capsular tissue. At an early-stage goals are composed of increasing deep perception, muscular stabilization, and neuronal control. Returning to an unrestricted level of activities is the main target, which will be achieved step by step. The program focuses on lowering shoulder pain and muscular inhibition by utilizing techniques such as cryotherapy or high voltage stimulation. Gentle motion exercises taking NSAIDs, and avoiding painful ROM arches are appropriate measures to reduce pain (11).

The final goal is to reinforce the RC strength and balance, shoulder blade posture, and core stabilization, as well as proprioception and neuromuscular control. Normal shoulder function, including sports, can be resumed if an appropriate strength has been achieved and symptoms like painful movements are diminished (5,11).

Isometric workouts for the glenohumeral stabilizers, especially the RC, help to prevent muscular atrophy and reflexive inhibition. Dynamic stability as a crucial point for a reinforcement can be trained by rhythmic stabilization drills or closed kinetic chain workouts, which should evenly enhance neuromuscular control. Axial compression at various positions, as well as the use of unstable surfaces, pose further challenges to stability (11).

Strength deficiencies, notably in the rotator cuff and scapular muscles, are corrected using a gradual isotonic strengthening program. Exercises include rotations, prone rowing, and scapular stabilization drills to improve proximal stability for functional tasks. The program also focuses on neuromuscular control with functional drills, proactive GH joint recentralization, proprioceptive neuromuscular facilitation (PNF), and plyometric workouts, which generate a reflexive muscular response and protect against future instability. Patients are encouraged to utilize the shoulder in secure positions and avoid activities that cause instability until they have gained sufficient strength and confidence. Bracing may be required for a return to sports in order to give controlled ROM and avoid future damage (11).

3.5.2 Surgical Treatment

Indications for surgery in cases of shoulder instability are varied but primarily include recurrent instabilities, acute complications, or specific needs for athletes. Surgical intervention is often required for patients who experience recurrent shoulder instabilities, particularly when nonoperative treatment have failed (3). Acute complication such as soft tissue insertion, rotator cuff injuries, biceps tendon enclosure in the joint capsule or glenoid rim fractures necessitate surgical intervention (3). Additionally, competitive athletes with serious instability lesion such as glenoidal fractures, labrum tears or a dislocation history may also require surgery to regain the full function and strength, as well as prevention of further injuries (3).

Various surgical procedures can be used for different kinds of shoulder instabilities. Bankart repair represents the first option in primary anterior shoulder dislocation in young individuals with a high demand of activities and confirmed Bankart lesion on MRI (3,5). This technique is mainly used when labral parts and capsular parts have separated from the glenoid. The goal of this operation represents the anchored refixation of glenoidal labrum back to its bony parts. This procedure can be executed arthroscopically after a good patient assortment with or without capsular shift. If performing a shift is necessary some needs to be watchful not to reduce the length of RC muscles (3,5). A repair technique developed by a surgeon called Millet, using so called portals, to see and work inside of the joint, the tissue firstly is debrided by a machine called shaver. The labral tear is gently removed from disturbing glenoidal parts for a good

reposition (27). If performing a shift is necessary some needs to be watchful not to reduce the length of RC muscles (3,5). During the past few years, the techniques for a Bankart repair have developed and adapted, so that new solutions for shoulder surgery are available (27).

A procedure called Remplissage is one of the modifications used with a Bankart repair (3,27). This method is frequently used in bigger impression fractures of humeral head. This should enhance the shoulders stabilization and diminished reoccurrence when combined. The meaning of the word itself describes the technique by filling up the Hill Sachs fracture in the back of the proximal humerus (3).

Capsular shift procedures, like anterior capsule shift are still common parts of instability surgery. This shift is also indicated in anterior shoulder instability especially when there is need of reducing the anterior capsular volume (3). The posteroinferior capsular shift is mainly used for posterior instabilities and can be done either arthroscopically or *via* an open strategy, involving superior shift of the posteroinferior capsule. This results in a reduced joint volume (3).

For significant bony defects, or glenoidal/humerus rotational correction an open approach might be necessary to choose (3). During a modified McLaughlin procedure, the humeral heads will be openly reduced. This is accompanied with the relocation of the lesser tuberosity and one of the RC muscles (subscapularis). This is primarily used to treat posterior shoulder instabilities (3).

For the treatment of a multidirectional instability the best approach could a capsular shift of the inferior capsule. This could also be performed either open or arthroscopically (3).

Laterjet and Bristow procedures are used in significant bone loss events or recurrent dislocations. In these procedures the coracoid process will be transferred towards the glenoid to enhance the joints stability (3,28). For the Laterjet procedure a short cut is made superior to the coracoid bone and retracting the deltopectoral triangle. After clearing the coracoid edges, the bone can be cut precisely. For placing the screws, two punctual holes are made. Further the subscapularis will be cut to free the glenoidal parts for positioning of the coracoid wedge, which will be secured by screws as well (29). This method can help to enhance the stabilization after a reoccurring dislocation (29).

A slightly different technique is performed after a surgeon called Bristow, where the coracoid is cut and only a centimeter is kept in place. A separation of the subscapularis muscle is performed, where the cut off parts of coracoid are threaded through, to be firmly positioned at the scapular neck (28).

Despite the potential benefits of surgical interventions, complications are likely to happen. Even after surgery the risk of recurrence of instability might not be excluded (3). Failure of material or infection can happen in those kinds of operations (28). Injuries of surrounding muscles and tendons and nerves can occur which can lead to a loss of motion (3,28). Capsular thinning or chondrolysis can result through overtightening the capsular shift or chondral injuries during the operation (3). Even though these operations are made for prevention of reoccurrence, it's still possible to appear (28) as well as late complications can occur like late osteoarthritis as a long term consequence (3).

4. Discussion

Shoulder instability is a prevalent condition occurring frequently in orthopedic medicine practices. It encompasses a spectrum of issues ranging from minor subluxations to complete dislocations, often triggered by trauma or hereditary factors (11). Anterior dislocations constitute 95% of these cases, with a significant proportion of patients requiring surgical intervention due to associated Bankart lesions (3). The occurrence of traumatic shoulder instability sums up to 2% in the general population, with 18% experiencing recurrent instability within a year post-dislocation (3). Multidirectional instability (MDI), though less common, presents substantial challenges for shoulder specialists, especially in patients with hypermobility conditions (3). These patients demonstrate a 3.3-fold increase in the risk of reoccurring instability, with surgical failures often linked to hyperlaxity (3).

The anatomy of the GH joint has a crucial role in understanding its instability. The main joint, GH joint, relies heavily on the integrity of its various ligaments and muscles for stability (4). The glenoid labrum, which enhances the glenoid fossa's volume and the glenohumeral ligaments are vital for maintaining static stability (4). Additionally, the RC muscles and the neurovascular structures, such as the axillary and suprascapular nerves, contribute to the shoulder's dynamic stability and extensive range of motion (4).

Shoulder instability is further classified into structural and non-structural types based on the Stanmore Instability Classification (5). This system helps differentiate between instability due to significant trauma, minor repetitive injuries, and muscle imbalance. For instance, anterior instability, often resulting from traumatic events, can lead to recurrent dislocations and requires careful imaging and surgical intervention to address potential bony defects and labral tears (6). Imaging techniques like MRI and MR arthrography are indispensable in diagnosing the extent of ligamentous and labral injuries, which are crucial for planning surgical repairs (6). Treatment modalities range from conservative rehabilitation, emphasizing muscle strengthening and proprioception, to various surgical procedures like Bankart repair and capsular shift, tailored to the type and severity of instability (3,11). Rehabilitative approaches, especially for atraumatic instability, focus on enhancing dynamic stability and neuromuscular control through progressive strengthening and proprioceptive exercises (11).

5. Conclusion

In conclusion, shoulder instability represents a complex clinical challenge that requires a multifaceted approach for effective management. A thorough understanding of the shoulder's intricate anatomy and the biomechanics underlying different types of instability is essential for precise diagnosis and treatment. The high prevalence of anterior instability and the substantial recurrence rates highlight the importance of prompt and appropriate intervention, particularly surgical repair in cases of significant structural damage. For patients with multidirectional instability, especially those with hypermobility syndromes, individualized treatment plans that address both structural and functional deficits are critical. Imaging modalities like MRI and MR arthrography provide invaluable insights into the extent of soft tissue and bony injuries, guiding both surgical and conservative treatment strategies. Rehabilitation programs play a pivotal role in restoring dynamic stability and neuromuscular control, emphasizing the importance of a comprehensive, patient-specific approach. Overall, the successful management of shoulder instability hinges on a detailed evaluation, precise classification, and tailored therapeutic interventions to ensure optimal outcomes and prevent recurrent instability. Continued research and advances in diagnostic and treatment modalities will further enhance our ability to manage this challenging condition effectively.

6. Summary

Shoulder instability, particularly of the glenohumeral joint, is common in nowadays medicine, ranging from minor subluxations to complete dislocations caused by trauma or hereditary factors. Anterior dislocations are the most prevalent, often necessitating surgical intervention for associated Bankart lesions. The incidence of traumatic shoulder instability is 1.7% in the general population, with significant recurrence rates. Multidirectional instability (MDI) is notable in patients with hypermobility conditions, increasing the risk of recurrent instability. The shoulder's stability depends on its complex anatomy, including ligaments, muscles, and neurovascular structures. The Stanmore Instability Classification helps categorize instability into structural and non-structural types. Imaging techniques such as MRI and MR arthrography are crucial for diagnosing ligamentous and labral injuries, but they are also essential for planning surgical repairs. Treatment involves both conservative rehabilitations, focusing on muscle strengthening and proprioception, and surgical interventions like Bankart repair and capsular shift, depending on the instability's type and severity. Effective management requires a comprehensive understanding of the shoulder's anatomy, accurate diagnosis, and individualized treatment plans to restore function and prevent recurrence. It is important to note that each patient must be viewed as an individual. Every information given in this thesis is retrospective statistics. The appropriate treatment and care must be provided for each patient individually.

Keywords: bankart repair, multidirectional instability, rehabilitation, shoulder instability

7. Literature

1. Haley CCA. History and Physical Examination for Shoulder Instability. *Sports Med Arthrosc Rev.* 2017 Sep;25(3):150–5.
2. Simons S, Dixon B. Physical examination of the shoulder. In. Available from: https://www.uptodate.com/contents/physical-examination-of-the-shoulder?search=Share%20%20Favorites%20%20Permissions%20DIGITAL%20EXCLUSIVE%20Anatomy%20and%20Physical%20Examination%20of%20the%20Shoulder&source=search_result&selectedTitle=1%7E150&usage_type=default&display_rank=1#H11044487
3. Akpinar S, Budeyri A. Surgical Management of Shoulder Instabilities. In: Huri G, Paschos NK, editors. *The Shoulder* [Internet]. Cham: Springer International Publishing; 2017 [cited 2024 Jun 16]. p. 415–41. (Orthopaedic Study Guide Series). Available from: http://link.springer.com/10.1007/978-3-319-51979-1_29
4. Bakhsh W, Nicandri G. Anatomy and Physical Examination of the Shoulder. *Sports Med Arthrosc Rev.* 2018 Sep;26(3):e10–22.
5. Solomon L, Warwick D, Nayagam S. *Apley's system of orthopaedics and fractures.* 9th ed. London: Hodder Arnold; 2010. 353–358 p.
6. Tuite MJ, Pfirrmann CWA. Shoulder: Instability. In: Hodler J, Kubik-Huch RA, Von Schulthess GK, editors. *Musculoskeletal Diseases 2021-2024* [Internet]. Cham: Springer International Publishing; 2021 [cited 2024 Jun 13]. p. 1–9. (IDKD Springer Series). Available from: https://link.springer.com/10.1007/978-3-030-71281-5_1
7. Varacallo M, Musto MA, Mair SD. Anterior Shoulder Instability. In: StatPearls [Internet]. Treasure Island (FL): StatPearls Publishing; 2024 [cited 2024 Jun 16]. Available from: <http://www.ncbi.nlm.nih.gov/books/NBK538234/>
8. Cofield RH, Kavanagh BF, Frassica FJ. Anterior shoulder instability. *Instr Course Lect.* 1985;34:210–27.
9. Sherman S. Shoulder dislocation and reduction. In 2024. Available from: https://www.uptodate.com/contents/shoulder-dislocation-and-reduction?search=instable%20shoulder&source=search_result&selectedTitle=1%7E150&usage_type=default&display_rank=1#H1
10. Cook TS, Stein JM, Simonson S, Kim W. Normal and variant anatomy of the shoulder on MRI. *Magn Reson Imaging Clin N Am.* 2011 Aug;19(3):581–94.
11. Wilk KE, Macrina LC, Reinold MM. Non-operative rehabilitation for traumatic and atraumatic glenohumeral instability. *North Am J Sports Phys Ther NAJSPT.* 2006 Feb;1(1):16–31.

12. Gottschalk LJ, Walia P, Patel RM, Kuklis M, Jones MH, Fening SD, et al. Stability of the Glenohumeral Joint With Combined Humeral Head and Glenoid Defects: A Cadaveric Study. *Am J Sports Med.* 2016 Apr;44(4):933–40.
13. Neer CS, Foster CR. Inferior capsular shift for involuntary inferior and multidirectional instability of the shoulder: a preliminary report. 1980. *J Bone Joint Surg Am.* 2001 Oct;83(10):1586.
14. Bak K, Spring BJ, Henderson JP. Inferior capsular shift procedure in athletes with multidirectional instability based on isolated capsular and ligamentous redundancy. *Am J Sports Med.* 2000;28(4):466–71.
15. Jaggi A, Alexander S. Rehabilitation for Shoulder Instability - Current Approaches. *Open Orthop J.* 2017;11:957–71.
16. Shoulder Instability – Anatomy & Causes (Video).
17. Housset V, Ho SWL, Läderrmann A, Phua SKA, Hui SJ, Nourissat G. Multidirectional instability of the shoulder: a systematic review with a novel classification. *EFORT Open Rev.* 2024 Apr 1;9(4):285–96.
18. MD Health. Shoulder Anterior Instability - Fact Sheet [Internet]. Available from: <https://mdhealth.com.au/fact-sheets/shoulder-anterior-instability-fact-sheet/>
19. Emond M, Le Sage N, Lavoie A, Rochette L. Clinical factors predicting fractures associated with an anterior shoulder dislocation. *Acad Emerg Med Off J Soc Acad Emerg Med.* 2004 Aug;11(8):853–8.
20. Gor DM. The trough line sign. *Radiology.* 2002 Aug;224(2):485–6.
21. Cisternino SJ, Rogers LF, Stufflebam BC, Kruglik GD. The trough line: a radiographic sign of posterior shoulder dislocation. *AJR Am J Roentgenol.* 1978 May;130(5):951–4.
22. Gosens T, Poels PJ, Rondhuis JJ. Posterior dislocation fractures of the shoulder in seizure disorders--two case reports and a review of literature. *Seizure.* 2000 Sep;9(6):446–8.
23. McFarland EG, editor. Examination of the Shoulder: The Complete Guide [Internet]. Stuttgart: Georg Thieme Verlag; 2006 [cited 2024 Jun 19]. Available from: <http://www.thieme-connect.de/products/ebooks/book/10.1055/b-002-66288>
24. Berkoff D. Multidirectional instability of the shoulder. In. Available from: <https://www.uptodate.com/contents/multidirectional-instability-of-the-shoulder#H6>
25. Robinson CM, Howes J, Murdoch H, Will E, Graham C. Functional outcome and risk of recurrent instability after primary traumatic anterior shoulder dislocation in young patients. *J Bone Joint Surg Am.* 2006 Nov;88(11):2326–36.
26. McAuliffe TB, Pangayatselvan T, Bayley I. Failed surgery for recurrent anterior

dislocation of the shoulder. Causes and management. *J Bone Joint Surg Br.* 1988 Nov;70(5):798–801.

27. Rashid MS, Arner JW, Millett PJ, Sugaya H, Emery R. The Bankart repair: past, present, and future. *J Shoulder Elbow Surg.* 2020 Dec;29(12):e491–8.

28. Cowling PD, Akhtar MA, Liow RYL. What is a Bristow-Latarjet procedure? A review of the described operative techniques and outcomes. *Bone Jt J.* 2016 Sep;98-B(9):1208–14.

29. Gartsman GM, Waggenspack WN, O'Connor DP, Elkousy HA, Edwards TB. Immediate and early complications of the open Latarjet procedure: a retrospective review of a large consecutive case series. *J Shoulder Elbow Surg.* 2017 Jan;26(1):68–72.

8. Curriculum vitae

Niclas Georg Olker was born on September 8th, 1995, in Cologne Germany. Mr. Olker started his medical career in 2014 with a training in the Maria Hilf Hospital in Bergheim, Germany. He completed this education in 2017 as certified Surgical technical assistant. In September 2018 he enrolled into the faculty of medicine in Rijeka, Croatia. During his studies Niclas was working as a surgical assistant in several hospitals in Germany.