

Progression of Age Related Maculopathy in Phakic Versus Pseudophakic Eyes

Kovačević, Damir; Mišljenović Vučerić, Tamara; Čaljkusić-Mance, Tea

Source / Izvornik: **Collegium antropologicum, 2010, 34 supplement 2, 21 - 23**

Journal article, Published version

Rad u časopisu, Objavljena verzija rada (izdavačev PDF)

Permanent link / Trajna poveznica: <https://um.nsk.hr/um:nbn:hr:184:693342>

Rights / Prava: [In copyright](#)/[Zaštićeno autorskim pravom.](#)

Download date / Datum preuzimanja: **2025-03-28**



Repository / Repozitorij:

[Repository of the University of Rijeka, Faculty of Medicine - FMRI Repository](#)



Progression of Age Related Maculopathy in Phakic Versus Pseudophakic Eyes

Damir Kovačević¹, Tamara Mišljenović Vučerić² and Tea Čaljkušić-Mance¹

¹ Department of Ophthalmology, Rijeka University Hospital, Rijeka, Croatia

² Eye Polyclinic »Dr. L. Pavičević«, Rijeka, Croatia

ABSTRACT

Age-related maculopathy (ARM) is one of the leading causes of central visual acuity loss in older western population. Many factors are responsible for the fast development of ARM. One of this is significant increases of optical radiations through artificial lens after removal of the catarctous lens. The aim of this study was to compare progression of ARM in phakic and pseudophakic patients and to calculate the possibility of pseudophakia as a risk factor for faster progression of ARM. Medical records of 76 patients, older than 60 years (32 male and 44 female) with early forms of ARM were randomly evaluated. They had undergone cataract removal by phacoemulsification with intraocular lens implantation from January 2002 to December 2006 at the Department of Ophthalmology, Rijeka University Hospital, Croatia. Patients were examined two weeks after the surgery and followed up for two years. The control group consisted of 48 patients (21 males and 27 females) with also early forms of ARM, older than 60 years, examined at the Polyclinic Department from January 2006 to December 2006 and followed up at least for two years without any cataract surgery. Comparing progression of ARM in these two groups, a total of 19 patients (25%) in pseudophakic group showed progression to late forms of ARM, but only 6 patients (12.5 %) in the control group developed these aggressive ARM forms. More aggressive forms of ARM in pseudophakic group indicate that pseudophakia should be considered as a risk factor for development of ARM.

Key words: pseudophakia, macular degeneration, lenses, intraocular, radiation, non-ionizing

Introduction

Age-related maculopathy (ARM) and cataract are leading causes of visual impairment in developed countries^{1,2}. Both are related to aging, and they share other risk factors, but it has been unclear whether a direct causal link might be involved.

Among many risk factors, the main risk factor for the development of advanced ARM is an increasing age. With age, the crystalline lens become yellowish and this accumulation of pigment in the lens eventually acts as a protective barrier against potentially damaging ultraviolet (UV) radiation and blue light³.

Various pathophysiological mechanisms have been discussed to explain a possible positive correlation between cataract surgery and late-stage ARM, including light toxicity during operation⁴, surgical trauma or inflammatory factors after surgery⁵⁻⁷ and increased light exposure after removal of the crystalline lens^{8,9}. Association between cataract surgery and ARM is pretty contro-

versial. While some studies have found no association between cataract surgery and ARM^{10,11} there are large population based studies supporting it^{12,13}.

In this study we compared progression of ARM in phakic and pseudophakic patients and we wanted to estimate the impact of pseudophakia as a potential risk factor for faster progression of AMD.

Patients and Methods

This is a retrospective study. ARM was defined on the basis of the International ARM Epidemiological Study Group classification¹⁴; early ARM by the presence of soft Drusen ($\geq 63 \mu\text{m}$) or hyperpigmentation and/ or hypopigmentation of the retinal pigment epithelium and late ARM by either neovascular age-related macular degeneration or geographic atrophy. Medical records of 76 patients (male:32; female:44) older than 60 years, with

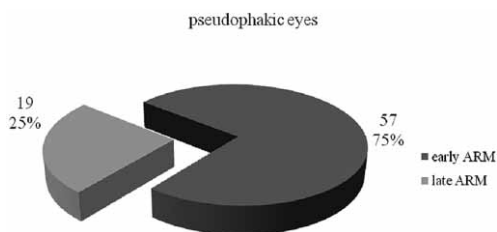


Fig. 1. Distribution of age-related maculopathy (ARM) in pseudophakic group in regard to the stage of disease.

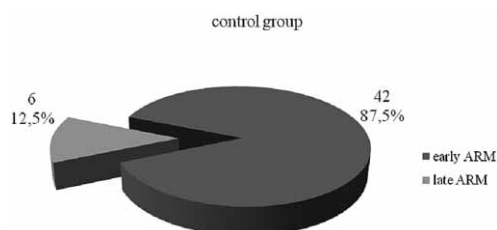


Fig. 2. Distribution of age related-maculopathy (ARM) in the control group in regard to the stage of disease.

early forms of ARM, were randomly evaluated. They had gone cataract removal by phacoemulsification with clear intraocular lens implantation. Operations were performed between January 2002 and December 2006 at the Department of Ophthalmology, Rijeka University Hospital. Patients were examined two weeks after surgery and followed up for two years. Visual acuity measurement, slit lam examination and stereo biomicroscopic fundus examination were performed.

Based on the exclusion criteria, high myopic patients (spherical equivalent ≥ 6.00 D) were not included in the study.

The control group consisted of medical records of 48 patients (male:21; female:27) older than 60 years, also with early forms of ARM. They were examined at Polyclinic Department in the period between January and December 2006 and followed up for two years, without any cataract surgery. Visual acuity measurement, slit lam examination and stereo biomicroscopic fundus examination were performed likewise.

REFERENCES

1. KLEIN R, WANG Q, KLEIN BE, MOSS SE, MEUER SM, Invest Ophthalmol Vis Sci, 36 (1995) 182. — 2. HYMAN L, Eye, 1 (1987) 330. — 3. MELLERIO J, Light effects on the retina. In: ALBERT DM, JAKOBIEC FA (Eds) Principles and Practice of Ophthalmology (Saunders, Philadelphia, 1994). — 4. LIBRE PE, Am J Ophthalmol, 136 (2003) 961. — 5. VAN DER SCHAFT TL, MOOY CM, DE BRUIJN WC, MULDER PG, PAMEYER JH, DE JONG PT, Br J Ophthalmol, 78 (1994) 441. — 6. CURKOVIC T, VUKOJEVIC N, BUČAN K, Coll Antropol, 29 (2005) 103. — 7. IVANČIĆ D, MANDIĆ Z, BARAĆ J, KOPIĆ M, Coll Antropol, 29 (2005) 55. — 8. SMITH BT, BELANI S, HO AC, Curr Opin Ophthalmol, 16 (2005) 166. — 9. KOVAČEVIĆ D, MISLJENOVIĆ T, NJIRIĆ S, MIKULIĆ M, VOJNIKOVIĆ B, Coll Antropol, 32 (2008) 9. — 10. BAATZ

Results

Comparing progression of ARM in these two groups, a total of 19 patients (25%) in pseudophakic group showed progression to late forms of ARM (Figure 1), but only 6 patients (12.5%) in the control group developed these aggressive ARM forms (Figure 2).

Discussion and Conclusion

AMD is responsible for 8.7% of all blindness (3 million people) due to eye disease, ranging from close to 0% in sub-Saharan Africa to 50% in industrialized countries. The number affected is expected to double by the year 2020 as a result of aging of the world's population¹⁵.

The prevalence of ARM is strongly age related. The etiology of ARM is still unclear, but is suspected to involve both external and internal factors^{16–19}. Cigarette smoking is the only risk factor other than age and ethnicity that has been constantly identified in numerous studies^{20–23}. In contrast, there is controversy over the role of other potential external factors, such as exposure to UV radiation^{24–28}.

The sunlight was one of the first agents recognized to be carcinogenic^{29,30}. There is data of large epidemiological studies suggesting that exposure to sunlight may be associated with age-related maculopathy^{31–34}.

With age, the crystalline lens becomes increasingly yellowish and the pigmentation protects the posterior pole of the eye by reducing the transmission of potentially harmful blue light and UV radiation^{3,35,36}.

Association between cataract surgery and ARM is still disputable. As we mentioned before, there are many factors such as intraoperative and postoperative ones that link cataract surgery and ARM^{4–9}.

In our study there was a considerable difference in progression of ARM in pseudophakic opposite phakic patients, but we were unable to separate different risk factors and we still don't know how much impact on these results has the natural protective function of yellow crystalline lens in adults.

In conclusion, more aggressive forms of ARM in pseudophakic group indicate that pseudophakia should be considered as a risk factor for development of ARM.

- H, DARAWSHA R, ACKERMANN H, SCHARIOOTH GB, DE ORTUETA D, PAVLIDIS M, HATTENBACH LO, Invest Ophthalmol Vis Sci, 49 (2008) 1079. — 11. SUTTER FK, MENGHINI M, BARTHELMES D, FLEISCHHAUER JC, KURZ-LEVIN MM, BOSCH MM, HELBIG H, Invest Ophthalmol Vis Sci, 48 (2007) 1472. — 12. CUGATI S, MITCHELL P, ROCHTCHINA E, TAN AG, SMITH W, WANG JJ, Ophthalmology, 113 (2006) 2020. — 13. PHAM TQ, CUGATI S, ROCHTCHINA E, MITCHELL P, MALOOF A, WANG JJ, Eye, 21 (2007) 512. — 14. BIRD AC, BRESSLER NM, BRESSLER SB, CHISHOLM IH, COSCAS G, DAVIS MD, DE JONG PT, KLAVER CC, KLEIN BE, KLEIN R, Surv Ophthalmol, 39 (1995) 367. — 15. GLOBAL INITIATIVE FOR THE ELIMINATION OF AVOIDABLE BLINDNESS, Action plan 2006–2011 (World

- Health Organization, Geneva, 2007) — 16. MEYERS SM, Trans Am Ophthalmol Soc, 92 (1994) 775. — 17. KLEIN R, KLEIN BE, TOMANY SC, MOSS SE, Am J Epidemiol, 156 (2002) 589. — 18. KHAN JC, THURLBY DA, SHAHID H, CLAYTON DG, YATES JR, BRADLEY M, MOORE AT, BIRD AC, Br J Ophthalmol, 90 (2006) 75. — 19. DESPRIET DD, KLAVER CC, WITTEMAN JC, BERGEN AA, KARDYS I, DE MAAT MP, BOEKHOORN SS, VINGERLING JR, HOFMAN A, OOSTRA BA, UITERLINDEN AG, STIJEN T, VAN DUJIN CM, DE JONG PT, JAMA, 296 (2006) 301. — 20. MACULAR PHOTOCOAGULATION STUDY GROUP, Arch Ophthalmol, 111 (1993) 1200. — 21. ROSENFELD PJ, BROWN DM, HEIER JS, BOYER DS, KAISER PK, CHUNG CY, KIM RY, MARINA STUDY GROUP, N Engl J Med, 355 (2006) 1419. — 22. TAP STUDY GROUP, Arch Ophthalmol, 117 (1999) 1329. — 23. BRESSLER NM, Arch Ophthalmol, 119 (2001) 198. — 24. TAYLOR HR, MUNOZ B, WEST S, BRESSLER SB, ROSENTHAL FS, Trans Am Ophthalmol Soc, 88 (1990) 163. — 25. TAYLOR HR, WEST S, MUNOZ B, ROSENTHAL FS, BRESSLER SB, BRESSLER NM, Arch Ophthalmol, 110 (1992) 99. — 26. CRUICKSHANKS KJ, KLEIN R, KLEIN BE, Arch Ophthalmol, 111 (1993) 514. — 27. TOMANY SC, KLEIN R, KLEIN BE, Ophthalmology, 110 (2003) 1526. — 28. DARZINS P, MITCHELL P, HELLER RF, Ophthalmology, 104 (1997) 770. — 29. MATSUMURA Y, ANANTHASWAMY HN, Toxicol Appl Pharmacol, 195 (2004) 298. — 30. SITUM M, BULJAN M, OTANIĆ BULIĆ S, SIMIĆ D, Coll Antropol, 31 (2007) 13. — 31. CRUICKSHANKS KJ, KLEIN R, KLEIN BE, Arch Ophthalmol, 111 (1993) 514. — 32. PLESTINA-BORJAN I, KLINGER-LASIĆ M, Coll Antropol, 31 (2007) 33. — 33. NJIRIĆ S, MISLJENOVIĆ T, MIKULIČIĆ M, PAVIČEVIĆ L, Coll Antropol, 31 (2007) 107. — 34. VOJNKOVIĆ B., NJIRIĆ S, COKLO M, SPANJOL J, Coll Antropol, 31 (2007) 43. — 35. LUI IY, WHITE L, LA CROIX AZ, Am J Public Health, 79 (1989) 765. — 36. LERMAN S, N Engl J Med, 319 (1988) 1475.

D. Kovačević

*Department of Ophthalmology, Rijeka University Hospital, Krišimirova 42, 51 000 Rijeka, Croatia
e-mail: damir.kovacevic@ri.t-com.hr*

PROGRESIJA SENILNE MAKULARNE DEGENERACIJE U OČIMA S PRIRODNOM LEĆOM U ODNOSU PREMA OČIMA S UMJETNOM LEĆOM

SAŽETAK

Senilna makularna degeneracija (SMD) je jedan od vodećih uzroka gubitka centralnog vida kod starijih osoba u zapadnom svijetu. Mnogi faktori uzrokuju brzu progresiju SMD. Jedan od njih je značajno povećanje propusnosti optičkih radijacija kroz umjetnu leću. Cilj ove studije je bio usporediti progresiju SMD u očima sa prirodnom lećom u odnosu prema očima sa umjetnom lećom, te na taj način procijeniti utjecaj pseudofakije kao potencijalnog faktora rizika u brzjoj progresiji SMD. Ovo je retrospektivna studija u kojoj su nasumce analizirane povijesti bolesti 76 pacijenata (muških 32; ženskih 44), starijih od 60 godina, s početnim stadijem SMD. Učinjena je operacije mrežne metodom fakoemulzifikacije, te je ugrađena prozirna intraokularna leća u razdoblju od siječnja 2002. do prosinca 2006. na Očnoj Klinici, KBC Rijeka. Pacijenti su pregledani dva tjedna nakon operacije, a zatim praćeni kroz dvije godine. Kontrolna skupina sastojala se od 48 pacijenata (muških 21; ženskih 27) također s početnim stadijem SMD, starijih od 60 godina, na Poliklinici u razdoblju od siječnja do prosinca 2006. Praćeni su kroz dvije godine, a nikome nije učinjena operacija mrežne. Usporedbom progresije SMD u ove dvije skupine, u ukupno 19 pseudofaknih pacijenata (25%) došlo je do progresije SMD u uznapredovali stadij bolesti, za razliku od samo 6 pacijenata (12,5%) u kontrolnoj skupini. Agresivnije forme SMD kod pseudofaknih pacijenata ukazuju da bi se pseudofakija trebala razmotriti kao jedan od faktora rizika u razvoju SMD.