

# New-onset lichen planus and lichen planus flare in elderly women after Covid -19 vaccination

---

Hlača, Nika; Žagar, Tina; Kaštelan, Marija; Peternel, Sandra; Brajac, Ines; Prpić-Massari, Larisa

Source / Izvornik: **Journal of Cosmetic Dermatology, 2022**

**Journal article, Published version**

**Rad u časopisu, Objavljena verzija rada (izdavačev PDF)**

<https://doi.org/10.1111/jocd.15185>

Permanent link / Trajna poveznica: <https://urn.nsk.hr/urn:nbn:hr:184:101782>

Rights / Prava: [In copyright](#) / [Zaštićeno autorskim pravom.](#)

Download date / Datum preuzimanja: **2025-03-22**



Repository / Repozitorij:

[Repository of the University of Rijeka, Faculty of Medicine - FMRI Repository](#)



## LETTERS TO THE EDITOR

# New-onset lichen planus and lichen planus flare in elderly women after COVID-19 vaccination

Dear Editor,

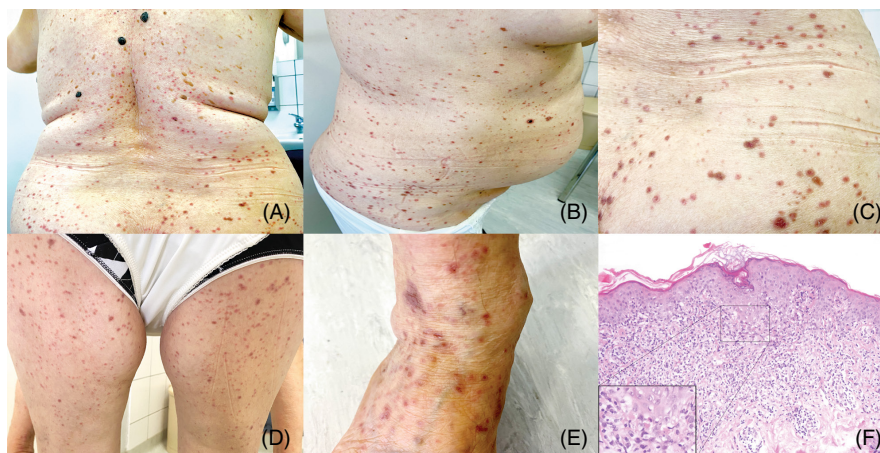
Owing to the widespread use of COVID-19 vaccines, the number of cutaneous vaccine-related adverse events has recently increased.<sup>1</sup> We present two cases of lichen planus in elderly women following COVID-19 mRNA vaccination. The first patient presented with new-onset LP, whereas the second patient experienced an extensive LP flare after a 10-year remission.

The first patient was an 82-year-old woman who developed an extensive pruritic rash 14 days after receiving a second dose of the Pfizer-BioNTech COVID-19 vaccine. Other possible triggers such as recent infections, medication changes, or stressful events preceding the eruption were ruled out. The patient had no significant medical history, other than well-controlled arterial hypertension. On physical examination, she had polygonal, purpuric, scaly papules in the axillary region, flexural wrists and forearms, ankles, buttocks, lower back, and abdomen (Figure 1). Mucosal lesions were not observed. Dermoscopy revealed mild desquamation and Wickham's striae. Skin biopsy demonstrated irregular epidermal hyperplasia with hypergranulosis and hyperkeratosis, vacuolar degeneration of the basal layer, and dense lymphocytic infiltrate in the superficial dermis (Figure 1). Considering the clinical presentation, histopathological analysis, and absence of an alternative trigger, we diagnosed LP triggered by the mRNA COVID-19 vaccine. Thus, we began treatment with prednisolone 20 mg daily, tapering

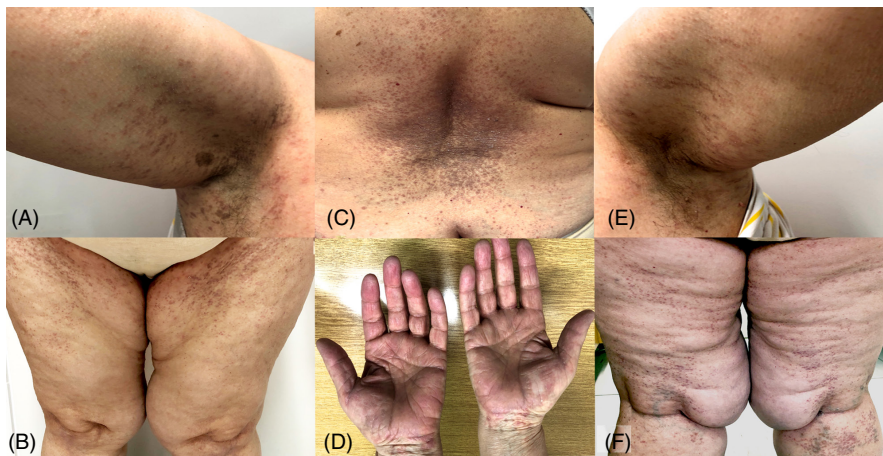
the dose over 6 weeks, which resulted in gradual improvement of skin lesions.

The second patient was a 68-year-old woman with a 2-week history of an intensely pruritic eruption that occurred 14 days after receiving a second dose of the Moderna COVID-19 (mRNA-1273) vaccine. Her medical history included arterial hypertension, hyperlipidemia, obesity, HLA-B27 spondyloarthritis, and LP, which was histologically confirmed 10 years ago and successfully treated with systemic and topical corticosteroids. During the examination, erythematous to violaceous squamous papules were discovered on the trunk, buttocks, and extremities, as well as around the ankles, flexural wrists, forearms, and axillary folds, with palmar involvement as well (Figure 2). Mucosal or nail lesions were absent. Dermoscopy revealed slight scaling and Wickham's striae, and a skin biopsy confirmed lichen planus. Therefore, we introduced 30 mg prednisolone, and tapered the dose to discontinuation over 6 weeks, which lead to the resolution of skin lesions.

LP is a chronic inflammatory T-cell-mediated skin disease caused by various infections, drugs, and, in rare cases, vaccines.<sup>1-6</sup> The most common vaccines causing LP are hepatitis B and influenza vaccines. Recently, the new-onset or reactivation of LP has been associated with COVID-19 infection and vaccination. Although most reported cases of LP following COVID vaccination were localized, we observed two cases of widespread LP.<sup>2-5</sup> The majority of vaccine-related



**FIGURE 1** Clinical presentation of extensive LP (A–E) with widespread purple scaly papules on the trunk and extremities and magnified detail of the lesions on the trunk (C). Skin biopsy (F) from the lower abdomen showing irregular epidermal hyperplasia with focal hypergranulosis, hyperkeratosis, and a band-like lymphocytic infiltrate obscuring the dermoepidermal junction (H&E, 200× magnification), along with vacuolar degeneration of the basal epidermal layer and individual apoptotic keratinocytes (inset, 400× magnification)



**FIGURE 2** Lichen planus eruption (A–F) presenting with erythematous, squamous papules, and hyperpigmented plaques involving both axillary regions, back, thighs, and flexural wrists

reactions occur in middle-aged women, implying an increased risk of such reactions in women, even in elderly ones, as observed in our cases.<sup>1,6</sup> Both our patients developed LP 14 days after receiving the second dose of mRNA COVID-19 vaccine, which is consistent with vaccine-related LP time onset.<sup>6</sup> The immunopathogenesis of vaccine-induced LP likely involves Th1 cell activation with upregulation of proinflammatory cytokines IL-2, TNF- $\alpha$ , and IFN- $\gamma$ , which leads to apoptosis of basal keratinocytes, a hallmark of LP. However, the precise mechanism underlying LP (re)activation following vaccination remains unknown. Similarly, immune dysregulation after COVID-19 vaccination may result in the (re)activation of other immune-mediated skin diseases such as psoriasis, vitiligo, acne vulgaris, pemphigus vulgaris, and certain connective tissue diseases.<sup>2,5</sup> Likewise, COVID-19 pandemic has underlined the importance of dermatologists and rheumatologists in providing guidance regarding immunosuppressive and biological therapy considering their extensive experience with such treatments, as well as recognizing the immune-mediated aspects of COVID-19 infection and vaccination.<sup>7</sup> Furthermore, as a result of a better understanding of COVID-19 disease mechanisms, novel therapeutic strategies utilizing adipose-derived mesenchymal stem cells (AD-MSCs) are being developed, and given their immuno-modulatory properties, could be employed to combat the disease.<sup>8</sup> Finally, dermatologists should be aware of new-onset or flare-ups of LP in older women caused by COVID-19 vaccination as well as the possible (re) activation of other immune-mediated skin diseases.

#### AUTHOR CONTRIBUTIONS

N.H. wrote the original manuscript. T.Z., S.P., and I.B. performed literature research and contributed to the analysis of the data. M.K. and L.P.M. performed supervision, and writing—review and editing.

#### CONFLICT OF INTEREST

The authors declare no conflicts of interest.

#### ETHICAL APPROVAL

Authors declare human ethics approval was not needed for this study.

#### DATA AVAILABILITY STATEMENT

The data that support the findings of this study are available from the corresponding author upon reasonable request.

#### PATIENT CONSENT

Written informed consent was obtained from the patients for the publication of this case report and accompanying images.

Nika Hlaca MD<sup>1,2</sup>

Tina Zagar MD<sup>1,2</sup>

Marija Kastelan MD, PhD<sup>1,2</sup>

Sandra Peternel MD, PhD<sup>1,2</sup>

Ines Brajac MD, PhD<sup>1,2</sup>

Larisa Prpic-Massari MD, PhD<sup>1,2</sup>

<sup>1</sup>Department of Dermatovenerology, Clinical Hospital Centre Rijeka, Rijeka, Croatia

<sup>2</sup>Faculty of Medicine, University of Rijeka, Rijeka, Croatia

#### Correspondence

Tina Zagar, Department of Dermatovenerology, Clinical Hospital Centre Rijeka, Croatia, Faculty of Medicine, University of Rijeka, Rijeka, Croatia.  
Email: [tinazagar89@gmail.com](mailto:tinazagar89@gmail.com)

#### ORCID

Nika Hlaca <https://orcid.org/0000-0002-0517-5462>

Tina Zagar <https://orcid.org/0000-0002-0308-4057>

Marija Kastelan <https://orcid.org/0000-0002-8318-8031>

Sandra Peternel <https://orcid.org/0000-0001-8590-0451>

Ines Brajac <https://orcid.org/0000-0003-1491-7998>

Larisa Prpic-Massari <https://orcid.org/0000-0003-3572-6197>

#### REFERENCES

1. McMahon DE, Kovarik CL, Damsky W, et al. Clinical and pathologic correlation of cutaneous COVID-19 vaccine reactions including V-REPP: a registry-based study. *J Am Acad Dermatol.* 2022;86:113-121.

2. Hiltun I, Sarriugarte J, Martinez-de-Espronedada I, et al. Lichen planus arising after COVID-19 vaccination. *J Eur Acad Dermatol Venereol.* 2021;35(7):e414-e415.
3. Merhy R, Sarkis A-S, Kaikati J, El Khoury L, Ghosn S, Stephan F. New-onset cutaneous lichen planus triggered by COVID-19 vaccination. *J Eur Acad Dermatol Venereol.* 2021;35(11):e729-e730.
4. Masseran C, Calugareanu A, Caux F, Bohelay G. Extensive cutaneous lichen planus triggered by viral vector COVID-19 vaccination (ChAdOx1 nCoV-19). *J Eur Acad Dermatol Venereol.* 2021;36:e263-e265.
5. Zagaria O, Villani A, Ruggiero A, Potestio L, Fabbrocini G, Gallo L. New-onset lichen planus arising after COVID-19 vaccination. *Dermatol Ther.* 2022;11:e15374.
6. Lai YC, Yew YW. Lichen planus and lichenoid drug eruption after vaccination. *Cutis.* 2017;100:e6-e20.
7. Misra DP, Agarwal V, Gasparyan AY, Zimba O. Rheumatologists' perspective on coronavirus disease 19 (COVID-19) and potential therapeutic targets. *Clin Rheumatol.* 2020;39(7):2055-2062.
8. Gentile P. SARS-CoV-2: the "uncensored" truth about its origin and adipose-derived mesenchymal stem cells as new potential immunomodulatory weapon. *Aging Dis.* 2021;12(2):330-344.