

Femoroacetabular Impingement

Schall, Pirmin

Master's thesis / Diplomski rad

2023

Degree Grantor / Ustanova koja je dodijelila akademski / stručni stupanj: **University of Rijeka, Faculty of Medicine / Sveučilište u Rijeci, Medicinski fakultet**

Permanent link / Trajna poveznica: <https://um.nsk.hr/um:nbn:hr:184:346359>

Rights / Prava: [In copyright](#)/[Zaštićeno autorskim pravom.](#)

Download date / Datum preuzimanja: **2025-03-23**



Repository / Repozitorij:

[Repository of the University of Rijeka, Faculty of Medicine - FMRI Repository](#)



**UNIVERSITY OF RIJEKA
FACULTY OF MEDICINE**

**INTEGRATED UNDERGRADUATE AND GRADUATE UNIVERSITY STUDY OF
MEDICINE IN ENGLISH**

Pirmin Schall

FEMOROACETABULAR IMPINGEMENT

GRADUATION THESIS

Rijeka, 2023

**UNIVERSITY OF RIJEKA
FACULTY OF MEDICINE**

**INTEGRATED UNDERGRADUATE AND GRADUATE UNIVERSITY STUDY OF
MEDICINE IN ENGLISH**

Pirmin Schall

FEMOROACETABULAR IMPINGEMENT

GRADUATION THESIS

Rijeka, 2023

Thesis mentor: doc.dr.sc. Tomislav Prpić, dr.med

The graduation thesis was graded on _____ in
_____, before the Committee composed of the following members:

1. Prof. dr. sc. Veljko Šantić (Committee Head)
2. Prof. dr. sc. Dalen Legovic
3. Izv. prof. dr. sc. Zdravko Jotanović, dr.med

The graduation thesis contains 24 pages, 6 figures, 1 table, 44 references.

Thesis Table of Content

1.	Introduction	1
2.	Aims and objectives	2
3.	Literature Review of Femoroacetabular Impingement	3
3.1	History	3
3.2	Epidemiology	3
3.3	Morphology	4
3.3.1	<i>Cam Morphology</i>	<i>5</i>
3.3.2	<i>Pincer Morphology</i>	<i>6</i>
3.3.3	<i>Mixed-type Morphology</i>	<i>6</i>
3.4	Diagnosis.....	6
3.4.1.	<i>Physical examination</i>	<i>7</i>
3.4.2	<i>Radiographic imaging.....</i>	<i>8</i>
3.4.3	<i>Computed Tomography and Magnetic resonance imaging.....</i>	<i>12</i>
3.4.4	<i>Diagnostic injection</i>	<i>12</i>
3.5	FAI and osteoarthritis	13
3.6	Differential Diagnoses.....	14
3.7	Therapy	14
3.7.1	<i>Conservative regimen.....</i>	<i>15</i>
3.7.2	<i>Surgical regimen</i>	<i>16</i>
3.7.2.1	<i>Surgical treatment complications</i>	<i>17</i>
4.	Discussion.....	17
5.	Conclusion.....	18
6.	Summary.....	19
7.	Literature.....	20
8.	Curriculum vitae.....	24

List of abbreviations and acronyms

ACEA	<i>Anterior center edge angle</i>
AOS	<i>Anterior offset</i>
AP	<i>Antero-posterior</i>
CEA	<i>Center-edge angle</i>
CT	<i>Computed Tomography</i>
ECF	<i>Epiphyseolysis capitis femoris</i>
FABER	<i>Flexion abduction external rotation</i>
FADIR	<i>Flexion Adduction Internal Rotation</i>
FAI	<i>Femoroacetabular impingement</i>
FAIS	<i>Femoroacetabular impingement syndrome</i>
LCEA	<i>Lateral center edge angle</i>
MRA	<i>Magnetic Resonance Arthrography</i>
MRI	<i>Magnetic resonance imaging</i>
NSAIDs	<i>Nonsteroidal anti-inflammatory drugs</i>
OA	<i>Osteoarthritis</i>
ROM	<i>Range of motion</i>
RSLR	<i>Resisted straight leg raise</i>
SCFE	<i>Slipped capital femoral epiphysis</i>

1. Introduction

The occurrence of concerns within the hip joint, particularly during physical activity among young active adults, is a prevalent issue encountered in clinical practice. (1,2) Within this population, femoroacetabular impingement (FAI) is among the differential diagnoses for individuals presenting with groin pain. FAI delineates a hip-related injury, that is generated by a pathological connection among the head of the femur and the acetabulum. The term femoroacetabular impingement syndrome (FAIS) is also commonly used, distinguishing the ongoing symptomatic features within the FAIS in comparison to the FAI. (3) Abnormal contact within the hip joint occurs throughout the movement of the hip, which is attributed to morphological changes within the femoral head, junction between head-neck, or acetabulum. (4–6) The impingement is divided into the pincer-type morphology, the cam-type morphology, and the mixed-type morphology, which consist of a combination of both pincer and cam morphology.(5) Besides the three distinct morphological types of FAI, Sankar et. al defined five fundamentals essential for the diagnosis of FAI: abnormal morphology of the femur and acetabulum, abnormal contact between the two structures, a vigorous motion that results in abnormal contact and collision, presence of soft tissue damage and repetitious motion leading to continuous detriment. (5,7) Furthermore, to clarify the diagnosis of FAI, the Warwick consensus statement in 2016 was invented. (5,8) Patients suffering from FAI can present in multiple ways; often symptomatic features occur mildly for a long period of time with an abrupt onset of worsening clinical features. Nevertheless, FAI can be present in patients without any symptomatic features. (4) Patients claim symptoms arising after sitting for a long period, snapping hip, discomfort within the groin area or buttocks, clicking, locking, or even a limited range of motion can be present. (3,5) The diagnostic assessment of FAI should include a detailed anamnesis, specific diagnostic stress tests within the physical examination, and diagnostic imaging. (2,4,9) Impingement management offers a range of approaches, from conservative methods like physical therapy and intra-articular injections, to more invasive options like open or arthroscopic surgery.

2. Aims and objectives

This review paper aims to present an outline of the disease femoroacetabular impingement. The objectives of the review include a historical part, which tries to clarify the terminology of the FAI; epidemiology of FAI, including its prevalence, incidence, and risk factors; summarizes diagnostic options included within the assessment of the impingement; and discusses the treatment options for FAI, encompassing conservative and operative management. Overall, the aim of this review paper on FAI is to provide a thorough and up-to-date overview of this complex condition, involving its diagnosis, management, and outcomes.

3. Literature Review of Femoroacetabular Impingement

3.1 History

The use of the term Femoroacetabular impingement (FAI) has not been prevalent for an extended period. Myers et al. were the first to use the terminology of FAI in their study about an impingement complication after the performance of a periacetabular osteotomy in 1999. (6,10) The diverse morphologies of FAI have been in existence for a considerable period; however, the link between these morphologies and hip impingement or even the development of osteoarthritis (OA) has not yet been firmly established. A study by Matsumoto et al. clarified that cam and pincer morphology were already described in earlier times. A.W. Otto, a German pathologist, was one of the first, who mentioned a pincer-type morphology in his book published in 1824. Otto described a deep location of the femoral heads within the acetabulum of a female pelvis. (6,11) Similarly, the cam morphology was first outlined by Henle in 1855 as a classic bump deformity in the femoral head-neck junction. (12)

In 1898 the connection to hip impingement was first discovered by the British surgeon John Poland. (6,13) Wiberg was the first who elucidated the radiological confirmation of acetabular over-coverage in 1939, by using the center-edge angle (CEA) measurement. The cam morphology was indirectly confirmed by radiological images within a study performed by Elmslie et al. where they tried to identify the etiology of OA. (6,14)

Precise definitions and sensitive measurements developed by Nötzli et al. in 2002 and Eijer et al. in 2001 are crucial for the definition of the FAI. (6,15,16) Nötzli defined the cam abnormality via the determination of the alpha angle on axial magnetic resonance imaging. The head-neck offset on radiological images was characterized by Eijer. (15,16)

3.2 Epidemiology

Regarding the epidemiology of the FAI, it is rather challenging to identify the clear prevalence of the different types of morphologies. Different studies included different groups of patients, which therefore led to different results in the occurrence of the impingement. A definite agreement between the different studies has shown, that the cam morphology occurs earlier in life, more often in athletes performing high-impact sports, and is more prevalent in the male

population. (4,5,17) The pincer-type FAI on the contrary develops more often in the female population and occurs later in life. In addition, mentioning the prevalence of mixed-type FAI is the most common one according to Trigg et al. and Chiari et al. but difficult to quantify its occurrence. (5) Furthermore, assistance in the diagnosis of FAI is provided by a consensus statement, which was developed by the Warwick Agreement in 2016. (5,8)

In the table (Table 1) below, the basic elements of the consensus statement are defined.

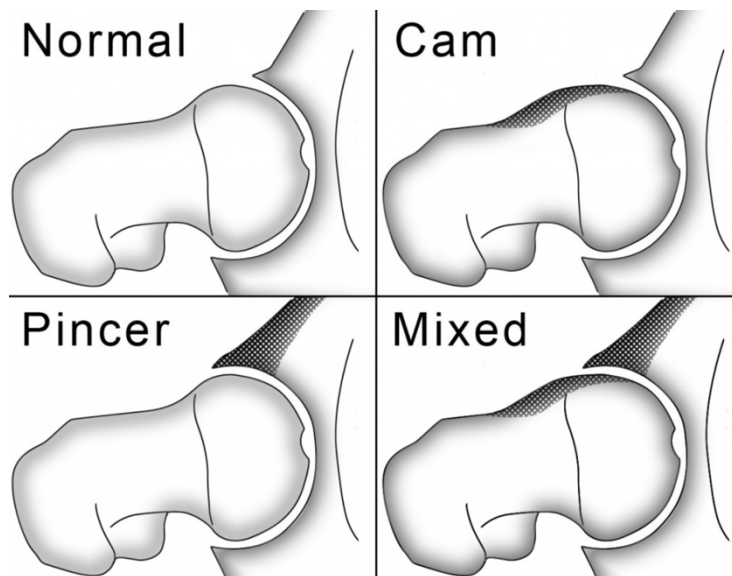
Table 1: Warwick consensus statement questions (5)

2016 Warwick consensus statement questions.

Questions	Consensus
What is FAI syndrome?	FAI syndrome is a motion-related clinical diagnosis of the hip that represents symptomatic contact between the proximal femur and the acetabulum.
How should FAI syndrome be diagnosed?	Symptoms, clinical signs, and imaging findings must be present to diagnose FAI syndrome.
Symptoms	FAI syndrome commonly has motion-related or position-related pain in the hip or groin. Patients also may describe clicking, catching, locking, stiffness, restricted range of motion, or giving way.
Clinical signs	The diagnosis of FAI syndrome does not depend on a single clinical sign. The FADIR test is sensitive but not specific for FAI syndrome. Internal rotation of the hip is commonly restricted.
Diagnostic imaging	Obtain an AP radiograph of the pelvis and a lateral femoral neck view of the symptomatic hip. Advanced imaging can be considered to further assess the morphological changes of the hip and the surrounding soft tissue.
What is the appropriate treatment of FAI syndrome?	FAI syndrome can be treated by various techniques discussed throughout the article to include conservative care, rehabilitation, or surgery.
What is the prognosis of FAI syndrome?	Most patients can return to full activity, including sports, with treatment. OA appears to be a long term outcome of cam morphology. However, it is currently unknown whether treatment for FAI syndrome prevents hip OA.
How should someone with an asymptomatic cam or pincer morphology be managed?	Rehabilitation techniques with core and pelvic stability can be recommended. However, it is unknown whether these individuals will progress to FAI syndrome.

3.3 Morphology

The FAI implies a combination of signs and symptoms accompanied by morphological changes within the femoral head-neck and/or at the acetabulum. It embodies with pain around the groin area due to the pathological anatomy of the hip joint combined with burdensome movements, leading to repetitive contact and damage. To define the FAI five critical points are needed to be fulfilled according to Sankar et al.: an abnormal morphology of the femur and/or acetabulum, the existence of soft tissue damage, repetitive movements which result in continuous insults, abnormal anatomical contact between hip and pelvis, and vigorous supraphysiologic motion which results in an abnormal contact. (5,7) In general, the FAI can be divided into three types of morphologies: the cam morphology, the pincer morphology and a mixed type morphology. (4,5) (Picture 1)



Picture 1. Types of morphologies in FAI (18)

3.3.1 Cam Morphology

The cam morphology can be described as an abnormal contour of the anterior/superior femoral junction between head and neck, whereas the acetabulum has an physiologically and morphological normal shape. (19) Furthermore, the cam morphology must be divided into a primary and secondary type. The primary form predominantly occurs in young adolescents during their skeletal maturation, without having any pre-existing diseases of the hip. This type manifests as a physiological response to repetitive, enduring, burdensome physical activities. Physical activities such as Ice hockey, Football, Volleyball, Gymnastics, and Athletics can be predisposing activities for developing a primary cam morphology. In response to the incriminating exercise, the hip adjusts its morphological features via epiphyseal extension or epiphyseal hypertrophy. (17) This development can be seen on both hips simultaneously. The primary cam morphology shows a natural reaction to shear forces and micro-traumas, where the body replies with a cupping phenomenon, which implies a phenomenon trying to stabilize the hip. (17) A critical point in the quantification of cam morphology, is the measurement of the alpha-angle by Nötzli on X-ray. (17) Additional characterization can be done by calculation of the triangular-index (Gosvig's-Index) on the radiological image. The index tries to identify the asphericity of the femoral head. (20)

In Contrast to the primary cam morphology, the secondary cam morphology occurs due to pre-existing injuries or deformities. One of the main reasons is Epiphyseolysis capitis femoris (ECF) or called slipped capital femoral epiphysis (SCFE). Differences between the primary and

secondary cam morphology are the lack of epiphyseal extension and a posterior tilt of the epiphysis. Patients who suffer from a symptomatic deformity provide an indication for surgical procedures. Additional causes of the secondary cam morphology are Perthes disease, labral tears, inflammatory joint diseases, osteoarthritis of the hip, osteonecrosis, or dysplasia of the hip. (17,4)

3.3.2 Pincer Morphology

The development of the pincer morphology is characterized by an acetabular retroversion, or acetabular protrusion, or even in coxa profunda, which represents a deep, medial-lying acetabulum. This structure leads to an excessive coverage (focal or global) of the femoral head and neck, causing a reduction and/or limitation of the range of motion (ROM) of the hip, especially in the flexion, where the neck of the femur approaches the labrum. (3,4)

3.3.3 Mixed-type Morphology

The Mixed-type morphology encompasses both, a cam, and a pincer deformity. It is the result of malformations within the proximal femur and the acetabulum. (4,5,17)

3.4 Diagnosis

The FAI is difficult to diagnose since the onset of the impingement is often insidious, and many patients present with inconclusive signs and symptoms, or even without symptomatic features. A reliable diagnosis contains an appropriate anamnesis, diagnostic imaging, and diagnostically conclusive examination finding via provocative tests. (3–5)

In the part of history taking, it is crucial to identify the onset of symptoms. At the beginning of the FAI, the symptoms are often subtle, and patients claim pain in the groin area after sitting for a longer period (e.g., working at the desk, airplane flight, taking a long car ride), which releases after putting themselves up in a standing position. Other suggestive symptoms of FAI can be discomfort in the lateral hip, thigh, or even in the buttocks of the lower back. (3) In the early stages patients often ignore these symptoms and dismiss them as strains of the thigh musculature.

Most patients are young active adults, who perform sports on regular bases, where fast rotational movements of the legs, fast changes of direction during sport, high impacts, or sprinting are included. (21) These sports imply football, handball, ice hockey, athletics, combat sports, volleyball, ballet, and gymnastics.

After the insidious onset of the symptoms, patients may often describe an acute exacerbation of pain during their sportive activity, or even forcing them to stop performing their sport. During the anamnesis, patients may show the examiner a so-called “C-sign” when they try to localize the origin of the pain. This “C” is formed by placing the thumb on the anterior side of the affected hip, the palm on the lateral hip and the fingers pointing towards the buttocks, therefore cupping the greater trochanter. (4,5,9)

Additional symptoms which can be mentioned by patients are clicking of the hip, snapping, giving way, reduced active ROM, catching, locking, or stiffness within the affected groin area. (4,5,9)

3.4.1 Physical examination

For the physical examination of patients with suspected FAIS, the assessment of gait, the balance of single-leg stand, active/passive ROM tests in comparison of both sides and passive stress tests with palpation of the painful area is necessary. (5) Muscular disbalances, hinge mechanisms, and differences in the ROM can be indicative of FAI and help in the further evaluation of patients. Furthermore, the provocative Flexion-Adduction-Internal Rotation test (FADIR), also known as the anterior impingement test, is needed to identify the FAI. (3–5) During the procedure, the patient is lying in a supine position and the affected hip is passively moved into flexion, adduction, and internal rotation via the examiner. The test is conclusive if the maneuver produces pain within the hip area. According to Dijkstra et al, patients present with a reduction of internal rotation of the affected hip at 90 degrees of flexion and ten degrees of adduction. (4) In concomitance with the FADIR test, the Flexion-Abduction-External Rotation test (FABER) is performed for the identification of tears within the acetabular labrum. A positive result of the FABER test is reproduced, if patients mention pain within the affected hip or a reduction of ROM in comparison to the non-affected hip. (3) The sensitivity of the FADIR test for FAI is according to Terrell et al. 94%, but only a specificity of 8%. (4,9) Another provocative test that should be performed during the physical examination is the resisted straight leg raise test (RSLR), where the patient is asked to actively put his/her leg in 30-40 degrees hip flexion with an extended knee. The examiner administers a downward force on the

elevated leg, and the patient tries to resist the force. If patients specify pain or a muscular weakness is visible in comparison to the other leg, the test counts as positive. (3) Additionally, if patients show the Drehmann – sign; during active flexion of the hip, a spontaneous external rotation occurs; this could be a hint of SCFE and therefore a secondary cam morphology. (17) For a thorough physical examination, neurological tests should be included. Enabling the separation of the origin of pain within the groin area.

The diagnostic tests are part of the diagnostic procedure and cannot be solely seen as confirmatory assays of the FAI.

3.4.2 Radiographic imaging

Radiological imaging should always be included in the diagnostic procedure of the FAI. Certain techniques can be performed to identify the different morphologies of the FAI. It is necessary to perform a radiological image of the pelvis in at least two angles. One image in an antero-posterior (AP) angle and one x-ray image in an axial angle. The radiological images can convey important information concerning the anatomy of the femur and/or the acetabulum. Besides anatomical changes of the femoral head-neck junction or the location of the acetabulum, radiological images supply details about cystic formations around the affected joint, which occur due to cartilaginous damage within the labral-chondral transitional zone. (21) Furthermore, the modified Dunn, cross-table lateral, Faux-profile, or frog-leg technique should be used as diagnostic imaging. (3–5,17) In the AP pelvic images, a comparison of both hips can be identified, and accurate measurements can be performed. A pistol grip appearance can be seen in AP pelvis radiographs when a cam morphology is present. The femur shows a decreased offset and an additional aspherical femoral head, forming a hump on the femoral neck junction with an expand of the radius on the lateral side. (20) But important to mention, is that for the identification of a cam morphology the modified Dunn technique remains the best suitable option. This technique aims to visualize the point where the femoral head and the neck encounter on the anterior-superior aspect. (5) The determination of the alpha angle by Nötzli et al. in axial images is an essential part of the analyzation radiographic image. The alpha angle quantifies the degree of asphericity of the femoral head. This measurement is obtained by sketching a line through the center of the femoral neck and femoral head. Furthermore, a spherical line is delineated surrounding the femoral head, utilizing the spherical shape of the acetabulum as a guide to determine the radius of the ring. Another line is then added, originating from the center of the femoral head toward the anterolateral aspect of the head-neck junction

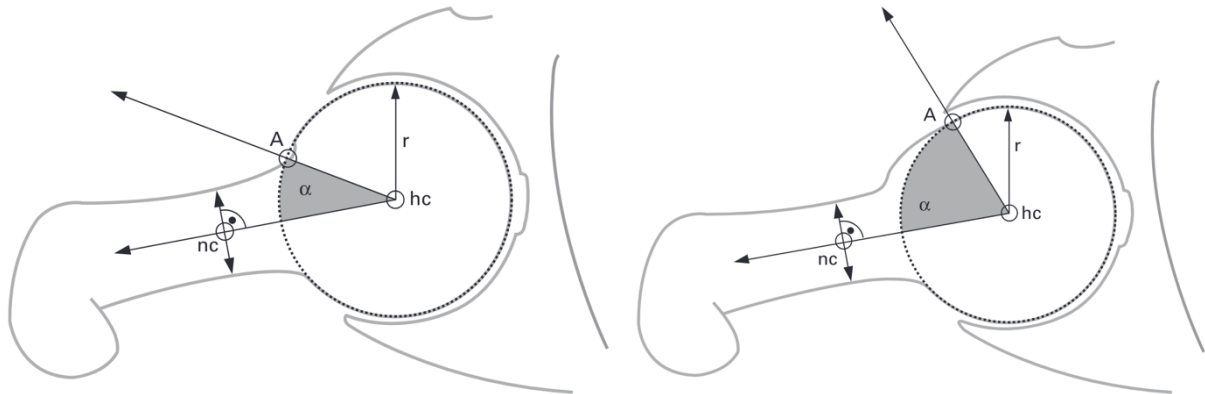
where the radius of the previously drawn sphere exceeds the normal morphology. (3) Alpha angles below 42 degrees are considered normal morphology. If the angle exceeds 55 to 60 degrees, a Cam morphology can be concluded. (3,5) (Picture 2) Similar to the alpha angle, the Triangular index (Gosvig's Index) can additionally be used to identify a Cam morphology in AP pelvic radiographs and axial images. The index is composed of certain measures on the radiographs: the radius (r) which represents the radius of the femoral head; the height (H) which is measured to the superior border of the femoral head-neck junction perpendicular to the half of the radius; and from the height a new radius (R) can be estimated by the usage of the Pythagorean axiom for right angle triangles. (Picture 3) (20) If the consequential R exceeds the natural radius of the head of the femur by two mm on 1.2 magnification, a cam morphology is present. (4,20) Besides these two measurements, the femoral head-neck offset is important in the estimation of anterior impingement in radiological images. The best suitable technique for the determination of the offset are cross-table lateral radiographs. Eijer et al. performed a retrospective analysis of radiographs including twenty-two patients, where twelve patients suffered from symptomatic hip pain and ten patients were asymptomatic. (16) Within the analysis, the anterior offset (AOS) is defined as the gap between one line from the femoral head center through the middle of the femoral neck and a third line that is drawn parallel and in contact with the anterior margin of the femoral head. (16,22) The ratio of the AOS is estimated by calculating the AOS divided with the diameter of the femoral head. (Picture 4)

The investigation revealed that in symptomatic patients suffering from anterior FAI, the AOS was significantly smaller than in comparison with asymptomatic hips. (16,23)

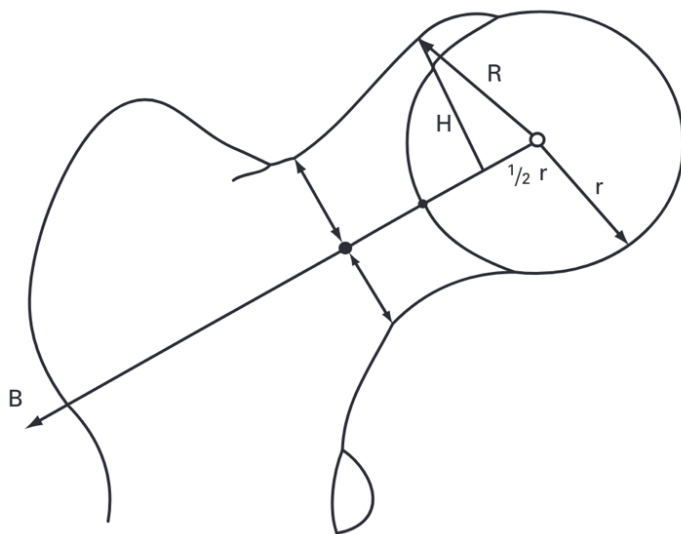
On the contrary, for identification of a pincer morphology a Faux-profile picture should be taken. (17) On AP pelvic radiographs the pincer morphology can be identified by analyzing the over-coverage of the acetabulum on the anterosuperior part. For the identification of the pincer-type FAI, measuring the lateral center edge angle by Wiberg (LCEA) on a Pelvic film should be performed. The angle is estimated by drawing one line from the center of the femoral head toward the lateral edge of the acetabulum. And sketching another line from the center of the femoral head vertically to the longitudinal axis of the pelvis. The angle between both lines is the resulting LCEA. (24) (Picture 5) An LCEA above 40 degrees is coherent with a pincer-type morphology. (5) An additional method utilized to identify the pincer morphology involves the application of the anterior center edge angle (ACEA), which was invented by Lequesne and de Seze. (25) The ACEA quantifies the extent of anterior coverage of the head of the femur relative to the acetabulum. Determining and calculation of the ACEA a false profile view is used as radiological image. Required lines for the measurement are one vertical line through the core

of the femur and one additional line from the center of the femur drawn towards the aspect of the acetabulum. (25,26) Angles in the range of 20 – 45 degrees are considered normal, while an ACEA surpassing this threshold indicate the presence of a pincer-type morphology. (25) (Picture 6)

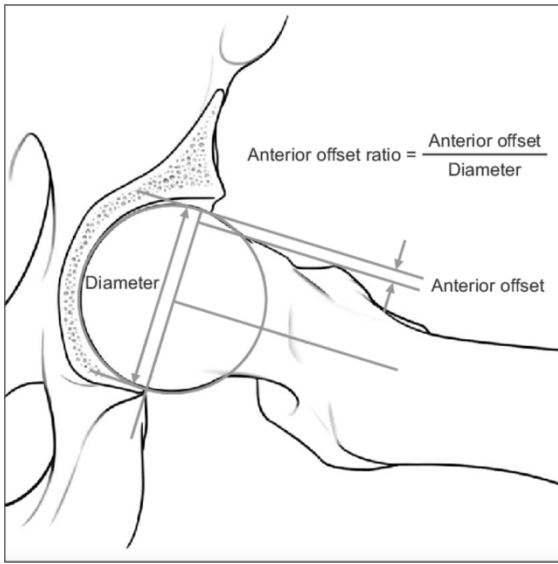
Radiologic Images which identified cam or pincer morphology and previous conclusive provocation tests are sufficient for the diagnosis of FAI. (4)



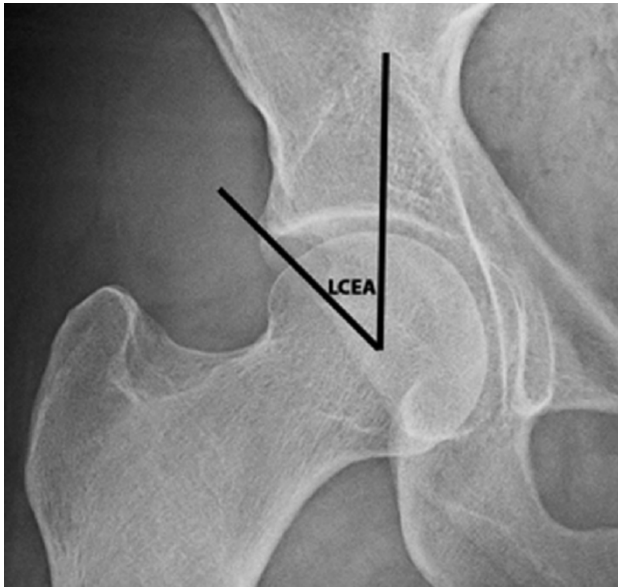
Picture 2. Alpha angle in a normal hip, and in a cam deformity, A = anterior point where the distance of the head center (hc) surpasses the radius (r); nc = neck center (15)



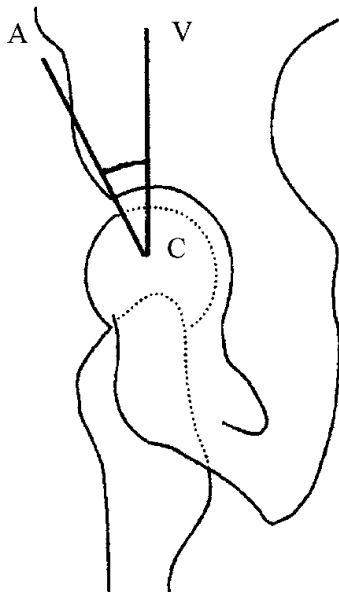
Picture 3. triangular index, assessment for cam morphology (20)



Picture 4. Anterior offset (22)



Picture 5. LCEA by Wiberg for determination of pincer morphology (27)



Picture 6. ACEA by Lequesne (C = center of femur; A = Acetabulum; V = Vertical) (28)

3.4.3 Computed Tomography and Magnetic resonance imaging

Computed tomography (CT) or magnetic resonance imaging (MRI) can be implemented in cases when plain radiographs are inconclusive. These techniques provide a three-dimensional image and deliver thorough information about the hip morphology and pathologies of the surrounding soft tissues. (4)

CT scans are well-suitable for the characterization and quantification of morphological features of the hip in a 3D manner. It is useful in the precise assessment of the alpha angle and the complete reconstruction of the asphericity of the femoral head-neck junction. A Downside of a CT-scan is the ionizing radiation for the patient and without contrast material soft tissues cannot be visualized. Nevertheless, CT scans help in the accurate analysis of the impingement and supply essential information in pre-operative planning. (4)

MRI can be a useful tool in the assessment of the FAIS. Before the analysis of the MRI, it is essential to portray in at least one sequence both hips to enable the comparison and to exclude a necrosis of the femoral head. (21) The MRI contributes vital information about any pathological changes within the surrounding soft tissues and shows intraarticular effusions, edema, or cystic formations around the affected joint. In case of a suspected FAI, the MRI is needed to clarify tears within the acetabular labrum, which can be found on the ventrolateral side in a cam-type FAI. (29) Furthermore, herniation-pits can be identified on MRI, which represent synovial invaginations on the transition of the femoral head towards the femoral neck. In contrast, in pincer-type FAI, the acetabular labrum is either completely degenerated or even ossified. Cartilaginous damage within the central part of the joint should be suspicious for a protruded acetabulum or coxa profunda in a pincer morphology. (21) Besides the conventional MRI, a magnetic resonance arthrography (MRA) can be conducted. In advance to performing this technique an intraarticular Injection with 0,1mM-Gadolinium-DTPA solution plus a local anesthetic is applied to the affected hip. The local anesthetic conducts a painless examination of the area and can provide information about intraarticular damage as well. The MRA should be performed within 30 minutes after the injection and it clarifies injuries within the acetabular labrum or the hyaline cartilage of the joint. (21,30,31)

3.4.4 Diagnostic injection

In addition to classic radiological imaging, CT, or MRI, a diagnostic injection of local anesthetics can be performed. In such a procedure, the patient is lying in the supine position,

and under the guidance of an x-ray or ultrasound a needle is inserted intraarticular. For confirmation, if the needle is within the correct place, iodine can be added as a contrast. A volume of around 5ml of local anesthetic is enough as a diagnostic injection tool. After the procedure, the patient is asked to rest for additional ten to fifteen minutes with flexed hips. This provides a good distribution of the local anesthetic. As a result of the injection, an analgetic effect should occur and therefore help the examiner to distinguish between an extra-articular or intra-articular origin of the symptoms. (21,32) However, Kivlan et al.'s research demonstrated that the presence of FAI pathology alone, without any chondral damage of the head of the femur or the acetabulum, did not lead to a significant alleviation of symptoms. (32,33)

3.5 FAI and osteoarthritis

FAI is a known risk factor for occurrence of osteoarthritis (OA) within the hip joint. It is possible, that patients may present with a pre-existing OA upon their initial medical evaluation, when FAI may be discovered as the underlying cause. (7,34) Unfortunately, after diagnosing the OA it is challenging to identify if a co-existing FAI is the reason for the disease, or if the FAI is a consequence of the OA. (7) Differences of anatomical structures within the femoral head-neck junction and/or the acetabulum can precede biomechanical disbalances and increased shearing forces inside the hip. The abnormal contact yields to tears within the acetabular labrum and attrition of the hyaline cartilage. Due to the deterioration and lacerations, the joint responds with an arthritic reaction. (5,7,34) Furthermore, a prospective study was performed by Agricola et al. where 1002 patients were included, and an AP pelvic radiograph was performed to identify the OA or a cam morphology. As a measurement technique, the alpha angle was inclined. In a two-to-five-year follow-up, the radiologic image was repeated. The results revealed that 76% of the portrayed hip joint had no osteoarthritic changes and 24% doubtful development of osteoarthritis. (7,35) Within five years, 2,76% evolved with a final stage OA. A pathologic alpha angle of more than 83 degrees has shown that the prevalence of end-stage OA was 9,66%. (35) According to Sankar et al. the presence of an alpha angle above 83 degrees and a diminished internal rotation of more than 20 degrees has a 53% pitfall for end-stage osteoarthritis. (7) Pistol grip appearance on radiologic images, which suspect a non-spherical head of the femur proved to be a risk factor for the evolution of OA according to the case-control study accomplished by Doherty et al. (36) The research revealed that out of the 965 patients with radiographic evident OA, the risk factor of a visual pistol grip appearance

was evident in 6,95% of the patients. (36) Based on the mentioned research it can be concluded that the morphologies of the FAI constitute risk factors for the evolution of an OA. Nevertheless, further investigation could accomplish more detailed prevalence, since the existence of an FAI itself is not sufficient enough to develop symptomatic OA. (7,34,36)

3.6 Differential Diagnoses

As the clinical symptoms of the FAI are unspecific and insidious, potential differential diagnoses are important to mention, and how to distinguish them from the FAI. The FAI is able to imitate other diseases of the hip or groin region. (2,4) Therefore, a clarifying anamnesis, physical examination, and diagnostic imaging are essential to identify the impingement. Illnesses of the hip and groin area especially in young active adults are challenging to recognize and therefore the differential workup is crucial. As before mentioned, patients may suffer from an acute aggravation of their symptoms due to specific motion, but a pre-existence of pain for a longer period. Pathologies which have to be incorporated in the differential diagnosis are the dysplasia of the hip, which can be identified via the Faux profile radiograph; Furthermore, SCFE can be evaluated with the Lauenstein – technique. (4,17) Muscle ailments that can mimic symptoms comparable to FAI are adductor tendinopathies, strains within the adductors, bursitis within the iliopsoas muscle, or strains within the m. iliopsoas. (2,4)

Stress fractures of the femur or the pelvis are often described by insidious onset and continuation of pain, and exacerbation of symptoms during sportive activities. With radiological imaging, these conditions can be separated from the FAI. (2,4)

Additionally to mention, nerve entrapments, tumors of the pelvic area, rheumatologic conditions, infections within the groin area, gynecological illnesses, and radiculopathies due to lumbar or sacral diseases should be investigated in the diagnostic procedure. (4)

3.7 Therapy

Subsequential to the confirmation of the FAI by the diagnostic procedure, it is recommended to initiate the correct management. Treatment options should be illustrated to patients. These options include operative interventions and conservative regimens. (3–5,37)

3.7.1 Conservative regimen

Nonoperative interventions include the education of patients, modification of lifestyle, medication with oral anti-inflammatory drugs (NSAIDs), intraarticular injection therapy and physical therapy. (5)

Physiotherapy should be the initial treatment approach in patients with FAI since most patients are younger and sportively active. The therapy approach carries a reduction of pain and should provide biomechanical improvement. Certain techniques for treatment imply core stability, proprioceptive exercises, amelioration of strength deficits within the musculature if detected, and dynamic stability training of the impacted hip. (5,17) Zogby et al. presented a five-year prospective research where they analyzed the effectiveness of conservative therapy in FAI. The research contained a six-week rest of the specific sport, physical therapy, and activity conversion. Patients who still suffered from symptomatic pain were offered intra-articular injections with a mixture of local anesthetic and corticosteroid. If the patient refused the injection, an arthroscopy was performed. The study included 67 hips in 50 patients and revealed, that in around 73% a non-operative treatment showed significant outcomes and enhancement of symptoms. 10% of the patients needed the intra-articular injection, and 17% underwent the arthroscopy. Within the first two years of the study, the improvement was much higher than in comparison with the later years. (17,38,39)

Important to mention is the return to the initial sport. In clinical practice, this remains a crucial question for the patients. This is a highly individual and circumstantial question since it is essential to include all patient-related factors. Therefore, the application of one generally valid answer is not possible. (4,5,17,38)

Besides physical therapy, oral analgesics can be provided for the patients, this focuses on relieving the symptomatic pain but does not treat the cause. Intra-articular injections with corticosteroids and local anesthetic show limited evidence of long-term effects on the FAI, but are a suitable method for differential diagnostics, whether the origin is intra- or extra-articular. A prospective cohort study including 54 patients with FAI revealed short-term pain relief and amelioration of symptoms on average for 9.8 days. (5,32,40) Furthermore, a study conveyed by Abate et al. has shown, that ultrasound-guided injection of hyaluronic acid can be used as a safe and effective treatment in mild FAI. (5,32,41) Unfortunately, only 23 hips were included in this study, nevertheless, it demonstrates the effect of hyaluronic acid in the disease.

3.7.2 Surgical regimen

Operative management proved to be a suitable method regarding the treatment of the FAI or the FAIS. The surgical procedure can be conducted through either an open or arthroscopic approach. Arthroscopy offers notable advantages, including a reduced likelihood of complications and a superior postoperative outcome. Therefore, the surgical technique which is used most often is the arthroscopy. (4) The purpose of a surgical procedure is the correction of the morphological changes within cam or pincer-type FAI. It can be ruled out by excision of the accessory bone on the head of the femur, or head-neck junction, which causes the impingement; additional assessment, reparation or resection of soft tissue damage of the acetabular labrum and the hyaline cartilage is needed. (4,5) The status of labral pathology plays a crucial role in decision, whether a refixation via suturing or a resection is needed during the arthroscopic procedure. Labral injuries can be complex, full thickness, or half thickness tears or a labral detachment from the acetabulum. (42) A study performed by Larson et al. revealed, that repair and labral refixation during the arthroscopic procedure have proven to be a better outcome for patients with FAI and labral damage. (43) Presurgical condition of the FAI is a crucial risk factor and predictive value in the outcome, the timing of development for osteoarthritis, the requirement for total hip replacement, or the possibility to convalesce the sport which was performed prior to surgery. Additionally, the kind of the sport, which was executed before surgery, and the personal level of competition should be considered as predictive factors. The retrospective cohort study performed by Stone et al. revealed that presurgical chondral damage, large alpha angles, a higher body mass index, mental health issues, symptoms for more than two years, and abnormal gait are negative predictive components of returning to high-level athletic function. (5,44) On the other hand, a meta-analysis and systematic review by Minkara et al. proclaimed that the ratio of return-to-play patients and patients reported outcomes after hip arthroscopy was significantly high. (5,45) Presence of a presurgical OA or a narrow joint space to a fewer extent than two mm among the femoral head and the acetabulum, are negative predictive values of the arthroscopic success and can be a risk factor for the possibility of reoperation according to Trigg et al. (5) Additional information in regard of the efficacy of arthroscopy is ubiquitous by the systematic review of Migliorini et al., where they analyzed available data of 406 adolescents, mean age of 15.9 years, and a follow-up to 30.4 months. The data concluded, that 94% of the patients rejoined their sportive activity. Complications developed in 1.1% of adolescents and revision procedures was

necessary in 4.7% of the patients. (17,46) The available data outlines the potency of surgical regimen in the clinical picture of FAI.

3.7.2.1 Surgical treatment complications

Important to mention, are complications which can occur accompanied by surgical treatment of the FAI. These complications can be divided into major and minor complications. The major complications include fractures of the femoral neck after an excessive resection of a cam deformity; pulmonary embolus, postoperative infection of the operated joint, and susceptibility to dislocation. (37) Minor complications on the other hand contain paresthesia of the thigh, hematomas, heterotopic ossification, and neuropraxia due to intraoperative traction. (37)

4. Discussion

Femoroacetabular impingement syndrome is a challenging disease, which can present with subtle clinical features and symptoms. Careful anamnesis, clinical testing, and diagnostic imaging are indispensable in the assessment of FAIS. Demanding factors within the anamnesis include the deceitful symptomatic features of the patient or even the non-existence of these. Numerous diseases in the groin region can present with almost similar clinical features as mentioned above in the part of the differential diagnosis. Therefore, structured precise evaluation of patients suffering from FAI is crucial. (2,4)

Additionally, the risk of OA within the hip joint developing later in life due to the pre-existence of a FAI provides further importance of the precise analysis and early initiation of treatment options. (8) Furthermore, early recognition of FAIS or thorough regular screening of young active adolescents performing sports, which are predestined for the development of FAI, could provide more useful data in regard to the diagnostic process and prevention of earlier disease progression. (17) With regard to the etiology of the disease, it remains unclear why the different types of FAI occur in some adolescents while other young adults engaging in the same sportive activity do not suffer from the disease. Further investigations are necessary to achieve conclusive evidence regarding the etiological factors behind its occurrence. (8) Diagnostic testing such as the anterior impingement test and the FABER are utilized during the physical exam of patients suffering from FAI. Different interpretations among examiners can appear during the examination and the tests are unfortunately insensitive for the disease. (8,9) Another

important fact to mention is the inaccuracy of diagnostic imaging and the necessity of different imaging techniques to draw precise conclusions. Improvement is needed in regard of choosing the most suitable imaging technique.

The efficacy of the arthroscopic approach in comparison to the effectiveness of physical therapy is well known. Nevertheless, a conservative approach preceding surgical treatment is admirable. Further studies are needed to exhibit the influence and success of physical treatment options. (5,17) Intra-articular injections as a diagnostic tool or for short-term amelioration of symptoms, can be considered, but their persuasiveness is still not sufficient enough and further investigations should be performed. (32)

5. Conclusion

In conclusion, the femoroacetabular impingement is an intra-articular hip condition, where abnormal contact occurs between the articular bones. The deformity can persist on either the femur, the acetabulum, or even on both. The impingement can lead to restricted movement, pain within the groin area, and if not addressed it may progress to hip osteoarthritis. The FAI should be diagnosed by combining history taking, physical examination with specific diagnostic stress tests, and diagnostic imaging techniques. The treatment options rely on the extend of the disease and include conservative regimen, such as physical therapy, rest, oral anti-inflammatory drugs, intra-articular injection, or surgical interventions such as arthroscopy or open hip surgery. Earlier detection and interventions can lead to superior outcome of patients and avoid long-term hip damage, especially in young athletes performing high-impact activities.

6. Summary

Femoroacetabular impingement (FAI) is a hip-related injury, which occurs commonly in young, active adults. The terminology of the FAI was first introduced by Myers et al. in 1999. The impingement proceeds due to a pathological interconnection between the femur and the acetabulum, and it can be classified into three different types of morphologies: the cam, pincer, and mixed morphology. Epidemiologically, the cam morphology occurs earlier in life and more often in males, as the pincer morphology is more common in females and appears later in life. The cam morphology is further distinguished into a primary and secondary type. In cam morphology, the pathology represents an irregular contour of the femoral head-neck junction, most often in the anterior/superior region. On the other hand, an over-coverage of the acetabulum is pathognomonic for the pincer-type. In the mixed type, both the cam morphology and the pincer morphology occur within the affected coxa. Assessment of FAI involves a thorough history taking, physical examination, and diagnostic imaging. Incorporated in the physical examination are the FADIR and FABER tests. For analysis of radiological images, it is useful to determine the alpha angle and the Gosvig's index to evaluate cam morphology, or the LCEA, which is used for pincer morphology. Besides x-ray, CT scans or MRI arthrography can be performed to clarify the disease. A known complication of the FAI is the development of osteoarthritis, which occurs due to misalignment of the femur or the acetabulum. Therapeutic options for the impingement are a conservative approach; including physical therapy, oral anti-inflammatory drugs, and intra-articular injections; or a surgical technique with an arthroscopic or open procedure.

Keywords: differential diagnoses, femoroacetabular impingement, therapeutic options

7. Literature

1. Langhout R, Weir A, Litjes W, Gozeling M, Stubbe JH, Kerkhoffs G, et al. Hip and groin injury is the most common non-time-loss injury in female amateur football. *Knee Surg Sports Traumatol Arthrosc.* 2019;27(10):3133–41.
2. Johnson R. Approach to hip and groin pain in the athlete and active adult.
3. Shaw C. Femoroacetabular Impingement Syndrome: A Cause of Hip Pain in Adolescents.
4. Dijkstra P, Glyn-Jones S. Femoroacetabular impingement syndrome.
5. Trigg SD, Schroeder JD, Hulsopple C. Femoroacetabular Impingement Syndrome. 2020;19(9).
6. Matsumoto K, Ganz R, Khanduja V. The history of femoroacetabular impingement. *Bone Jt Res.* 2020 Sep;9(9):572.
7. Sankar WN, Nevitt M, Parvizi J, Felson DT, Agricola R, Leunig M. Femoroacetabular Impingement: Defining the Condition and its Role in the Pathophysiology of Osteoarthritis. *Femoroacetabular Impingement.* 2013;21.
8. Griffin DR, Dickenson EJ, O'Donnell J, Agricola R, Awan T, Beck M, et al. The Warwick Agreement on femoroacetabular impingement syndrome (FAI syndrome): an international consensus statement. *Br J Sports Med.* 2016 Oct 1;50(19):1169–76.
9. Terrell SL, Olson GE, Lynch J. Therapeutic Exercise Approaches to Nonoperative and Postoperative Management of Femoroacetabular Impingement Syndrome. *J Athl Train.* 2021 Jan 1;56(1):31–45.
10. Myers SR, Eijer H, Ganz R. Anterior femoroacetabular impingement after periacetabular osteotomy. *Clin Orthop.* 1999 Jun;(363):93–9.
11. Otto AW. Seltene Beobachtungen zur Anatomie, Physiologie und Pathologie gehörig: Neue seltene Beobachtungen zur Anatomie, Physiologie und Pathologie gehörig. *Holäufers*; 1824. 190 p.
12. Henle J. *Handbuch der systematischen Anatomie des Menschen* v. 1 pt. 1-3, 1855-58. F. Vieweg; 1855. 832 p.
13. Traumatic separation of the epiphyses / by John Poland ... with 337 illustrations and skiagrams. [Internet]. Wellcome Collection. [cited 2023 Apr 4]. Available from: <https://wellcomecollection.org/works/u73w6ggy/items>
14. Elmslie RC. Remarks on AETIOLOGICAL FACTORS IN OSTEO-ARTHRITIS OF THE HIP-JOINT. *Br Med J.* 1933 Jan 7;1(3757):1-46.1.
15. Nötzli HP, Wyss TF, Stoecklin CH, Schmid MR, Treiber K, Hodler J. The contour of

- the femoral head-neck junction as a predictor for the risk of anterior impingement. *J BONE Jt Surg.* 2002;84(4).
16. Eijer H, Leunig M, Mahomed MN, Ganz R. Cross-Table Lateral Radiographs for Screening of Anterior Femoral Head-Neck Offset in Patients with Femoro-Acetabular Impingement. *HIP Int.* 2001 Jan 1;11(1):37–41.
 17. Chiari C, Lutschounig MC, Nöbauer-Huhmann I, Windhager R. Femoroacetabuläres Impingement-Syndrom bei Adoleszenten – Wie beraten? Wie behandeln? *Orthop.* 2022 Mar;51(3):211–8.
 18. Neeld K. Training Around Femoroacetabular Impingement [Internet]. Kevin Neeld. 2011 [cited 2023 May 1]. Available from: <https://www.kevinneeld.com/training-around-femoroacetabular-impingement/>
 19. Kassarian A, Brisson M, Palmer WE. Femoroacetabular impingement. *Eur J Radiol.* 2007 Jul 1;63(1):29–35.
 20. Gosvig KK, Jacobsen S, Palm H, Sonne-Holm S, Magnusson E. A new radiological index for assessing asphericity of the femoral head in cam impingement. *J Bone Joint Surg Br.* 2007 Oct 1;89-B(10):1309–16.
 21. Kusma M, Bachelier F, Schneider G, Dienst M. Femoroacetabuläres Impingement: Klinische und radiologische Diagnostik. *Orthop.* 2009 May;38(5):402–11.
 22. Figure 5. Anterior offset: the distance between the line from the... [Internet]. ResearchGate. [cited 2023 Apr 4]. Available from: https://www.researchgate.net/figure/Anterior-offset-the-distance-between-the-line-from-the-femoral-head-center-through-the_fig3_322123780
 23. Nemtala F, Mardones RM, Tomic A. Anterior and Posterior Femoral Head-Neck Offset Ratio in the Cam Impingement. *Cartilage.* 2010 Jul;1(3):238–41.
 24. Sheikh Z. Lateral centre-edge angle | Radiology Reference Article | Radiopaedia.org [Internet]. Radiopaedia. [cited 2023 Mar 31]. Available from: <https://radiopaedia.org/articles/lateral-center-edge-angle>
 25. Pauldhurai VK. Anterior centre-edge angle | Radiology Reference Article | Radiopaedia.org [Internet]. Radiopaedia. [cited 2023 May 23]. Available from: <https://radiopaedia.org/articles/anterior-center-edge-angle>
 26. Crockarell JR, Trousdale RT, Guyton JL. The anterior centre-edge angle: A CADAVER STUDY. *J Bone Joint Surg Br.* 2000 May;82-B(4):532–4.
 27. Figure 2. Anteroposterior radiograph demonstrating the lateral center... [Internet]. ResearchGate. [cited 2023 May 1]. Available from:

- https://www.researchgate.net/figure/Anteroposterior-radiograph-demonstrating-the-lateral-center-edge-angle-in-a-patient-with_fig2_260377851
28. A-diagram-illustrates-the-VCA-angle-on-the-false-profile-view-of-the-hip-The-angle-is.png.
 29. MR imaging of femoroacetabular impingement • APPLIED RADIOLOGY [Internet]. [cited 2023 Mar 31]. Available from: <https://appliedradiology.com/articles/mr-imaging-of-femoroacetabular-impingement>
 30. Aprato A, Massè A, Faletti C, Valente A, Atzori F, Stratta M, et al. Magnetic resonance arthrography for femoroacetabular impingement surgery: is it reliable? *J Orthop Traumatol*. 2013 Sep 1;14(3):201–6.
 31. Anderson LA, Peters CL, Park BB, Stoddard GJ, Erickson JA, Crim JR. Acetabular Cartilage Delamination in Femoroacetabular Impingement: Risk Factors and Magnetic Resonance Imaging Diagnosis. *JBJS*. 2009 Feb 1;91(2):305.
 32. Khan W, Khan M, Alradwan H, Williams R, Simunovic N, Ayeni OR. Utility of Intra-articular Hip Injections for Femoroacetabular Impingement. *Orthop J Sports Med*. 2015 Aug 31;3(9):2325967115601030.
 33. Kivlan BR, Martin RL, Sekiya JK. Response to diagnostic injection in patients with femoroacetabular impingement, labral tears, chondral lesions, and extra-articular pathology. *Arthrosc J Arthrosc Relat Surg Off Publ Arthrosc Assoc N Am Int Arthrosc Assoc*. 2011 May;27(5):619–27.
 34. Ganz R, Parvizi J, Beck M, Leunig M, Nötzli H, Siebenrock KA. Femoroacetabular Impingement: A Cause for Osteoarthritis of the Hip. *Clin Orthop Relat Res*. 2003 Dec;417:112.
 35. Agricola R, Heijboer MP, Bierma-Zeinstra SMA, Verhaar JAN, Weinans H, Waarsing JH. Cam impingement causes osteoarthritis of the hip: a nationwide prospective cohort study (CHECK). *Ann Rheum Dis*. 2013 Jun 1;72(6):918–23.
 36. Nonspherical femoral head shape (pistol grip deformity), neck shaft angle, and risk of hip osteoarthritis: A case–control study. [cited 2023 Apr 2]; Available from: <https://onlinelibrary.wiley.com/doi/10.1002/art.23939>
 37. O’Rourke RJ, El Bitar Y. Femoroacetabular Impingement. In: *StatPearls* [Internet]. Treasure Island (FL): StatPearls Publishing; 2023 [cited 2023 Apr 5]. Available from: <http://www.ncbi.nlm.nih.gov/books/NBK547699/>
 38. Zogby A, Bomar JD, Johnson KP, Upasani VV, Pennock A. Nonoperative Management of Femoroacetabular Impingement: Clinical Outcomes at 5-years – A

- Prospective Study: 2021 POSNA Annual Meeting – Best Clinical Award Paper. *J Pediatr Orthop Soc N Am* [Internet]. 2021 Aug 1 [cited 2023 Apr 5];3(3). Available from: <https://www.jposna.org/index.php/jposna/article/view/299>
39. Imam S, Khanduja V. Current concepts in the diagnosis and management of femoroacetabular impingement. *Int Orthop*. 2011 Oct;35(10):1427–35.
 40. Krych AJ, Griffith TB, Hudgens JL, Kuzma SA, Sierra RJ, Levy BA. Limited therapeutic benefits of intra-articular cortisone injection for patients with femoroacetabular impingement and labral tear. *Knee Surg Sports Traumatol Arthrosc*. 2014 Apr 1;22(4):750–5.
 41. Abate M, Scuccimarra T, Vanni D, Pantalone A, Salini V. Femoroacetabular impingement: is hyaluronic acid effective? *Knee Surg Sports Traumatol Arthrosc*. 2014 Apr 1;22(4):889–92.
 42. Schilders E, Dimitrakopoulou A, Bismil Q, Marchant P, Cooke C. Arthroscopic treatment of labral tears in femoroacetabular impingement: A COMPARATIVE STUDY OF REFIXATION AND RESECTION WITH A MINIMUM TWO-YEAR FOLLOW-UP. *J Bone Joint Surg Br*. 2011 Aug;93-B(8):1027–32.
 43. Larson CM, Giveans MR. Arthroscopic debridement versus refixation of the acetabular labrum associated with femoroacetabular impingement. *Arthrosc J Arthrosc Relat Surg Off Publ Arthrosc Assoc N Am Int Arthrosc Assoc*. 2009 Apr;25(4):369–76.
 44. Stone AV, Beck EC, Malloy P, Chahla J, Nwachukwu BU, Neal WH, et al. Preoperative Predictors of Achieving Clinically Significant Athletic Functional Status After Hip Arthroscopy for Femoroacetabular Impingement at Minimum 2-Year Follow-Up. *Arthrosc J Arthrosc Relat Surg*. 2019 Nov;35(11):3049-3056.e1.
 45. O'Connor M, Minkara AA, Westermann RW, Rosneck J, Lynch TS. Return to Play After Hip Arthroscopy: A Systematic Review and Meta-analysis. *Am J Sports Med*. 2018 Sep;46(11):2780–8.
 46. Migliorini F, Maffulli N. Arthroscopic Management of Femoroacetabular Impingement in Adolescents: A Systematic Review. *Am J Sports Med*. 2021 Nov;49(13):3708–15.

8. Curriculum vitae

Pirmin Beat Schall was born in February 1994 in Neuss, Germany. He is the second child of Mr. Dr. Hartmut Karl Schall and Mrs. Dr. Brigitte Schall. His Brother Urs Leonard Schall MD was born in 1991 and is currently working as a dentist. Mr. Hartmut Schall is working as a specialist in the field of Otorhinolaryngology and Mrs. Brigitte Schall has worked as a specialist of occupational medicine.

After finishing the elementary school 2004, Pirmin changed schools towards the Gymnasium until June 2012. After graduation with high school-diploma, he decided to start an apprenticeship as a physiotherapist at the “Sebastian – Kneipp Schule” in Bad Wörishofen. In 2015 he successfully completed the education as a physiotherapist and worked for one year in an ambulatory office. To enhance communication skills in English, Pirmin decided to travel in 2016 on a three-month trip through Canada. Subsequently he was working in a hospital and an ambulatory office for one year. He enrolled at the Faculty of Medicine in Rijeka in October 2017. Besides studying, Pirmin worked during the summer breaks in the ambulatory office and made internships in the field of orthopedics, traumatology, physical medicine, and rehabilitation.