

Ultrasonographically guided percutaneous therapy of lobar nephronia

Fučkar, Željko; Čohar, Franjo; Mozetič, Vladimir; Šustić, Alan

Source / Izvornik: **Radiologia Iugoslavica, 1991, 25, 201 - 204**

Journal article, Published version

Rad u časopisu, Objavljena verzija rada (izdavačev PDF)

Permanent link / Trajna poveznica: <https://um.nsk.hr/um:nbn:hr:184:609981>

Rights / Prava: [In copyright](#)/[Zaštićeno autorskim pravom.](#)

Download date / Datum preuzimanja: **2025-03-22**



Repository / Repozitorij:

[Repository of the University of Rijeka, Faculty of Medicine - FMRI Repository](#)



ULTRASONOGRAPHICALLY GUIDED PERCUTANEOUS THERAPY OF LOBAR NEPHRONIA

Fučkar Ž¹, Čohar F², Mozetič V³, Šustić A⁴

Abstract – In our patient the diagnosis of lobar nephronia (acute focal bacterial nephritis) was suspected on the basis of anamnesis, status, laboratory data and ultrasonography. A cytological examination of the specimen confirmed the diagnosis. Four times repeated instillation of Gentamycin (80 mg) »in loco« under ultrasound control resulted in the complete regression of local lesion.

UDC: 616.61-002-073:534-8

Key words: nephritis-therapy; ultrasonic therapy

Case report

Radiol Jugosl 1991; 25:201-4.

Introduction – Lobar nephronia (acute focal bacterial nephritis) is a clinical entity which can be defined as an acute local infection of renal parenchyma without liquefaction (1, 2). In 90% of cases the infection was caused by *e. coli* and rarely by *aerobacter aerogenes*, *pseudomonas aeruginosa*, *proteus* and *klebsiella* (3, 4). Clinical symptoms correspond to acute pyelonephritis.

Regarding ultrasonical examination the following possibilities should be considered in the differential diagnosis: mixed tumor, column of Bertini, hematoma, lymphoma, urinoma and cyst (1, 5, 6). Some specific characteristics of focal lesions such as poorly limited solid mass usually with low-level echoes which disrupt continuity of the corticomedullary border (1, 2) and physician's experience improve the diagnosis.

Ultrasonically guided puncture and cytological examination of the specimen are the methods of choice for final diagnosis (1, 4, 5, 7). Local topic antibiotic application (1, 5, 7) or ultrasonically controlled percutaneous drainage (1, 5, 7, 8) proved to be successful therapeutic procedures.

Case Report – A 58-year old man was referred to the Department of Nephrology (152/90) as an emergency case after an episode of left flank pain, high temperature and dysuria

during the last four days. He said that he had urinated blood several times. In the remaining history, he underwent malaria in childhood and a few attacks of erysipelas on the shin, joint inflammation and inflammation of the urinary system with symptoms which were similar with the present ones and passed spontaneously. Physical examination revealed positive left lumbar succussion and palpation tenderness of the lower half of left kidney area.

Laboratory data: urine lucid, yellow, sour, alb+ (4.3 g/l), sugar+ (1.6 mmol/l), acetone+. Microscopic specimen of urine: white blood cells, bacteria, 4-6 RBC. Urinoculture: *e. coli* (> 100.000 per ml), Hemoculture: *e. coli*, SR 80/, WBC 9.8 BS 14.1, urea 10.1, creatinine 149. All other biochemical investigations were normal.

After anamnesis, status and laboratory data the working diagnosis was: urosepsis, acute left-side pyelonephritis and diabetes mellitus.

An i. v. urography showed that the left kidney inefficiently concentrated contrast with pallid nephrographic effect and incapability of pyelocaliceal system analysis. The left kidney was enlarged with irregular borders which corresponded to an expansive process and further treatment was recommended.

Ultrasonography revealed gently hyperechoic area (2.6 x 2.3 cm) of the medial part of the left kidney which pressed echoes from the pyelocaliceal system. According to the sonographic findings, this focal lesion is probably column of Bertini. In the differential diagnosis lobar nephronia, which is often hypoechoic, has to be taken into consideration. The right kidney, liver and

gallbladder were sonographically normal. The prostate showed sonographic signs of chronic prostatitis with a few prostatoliths. Ultrasonically guided percutaneous puncture of the left kidney was recommended (Fig 1).

Ultrasonically guided puncture was done in the following way: the patient lied on the right

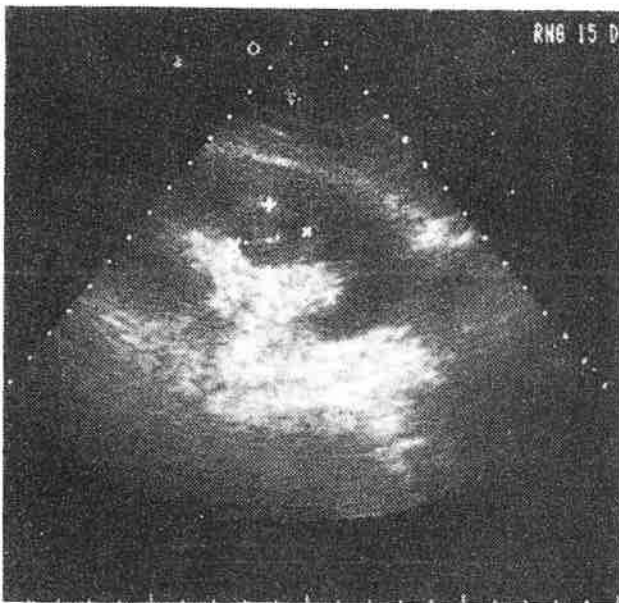


Fig. 1 – Dorsal axial sector scan of the left kidney with presentation of mesonephric focal lesion (markers)

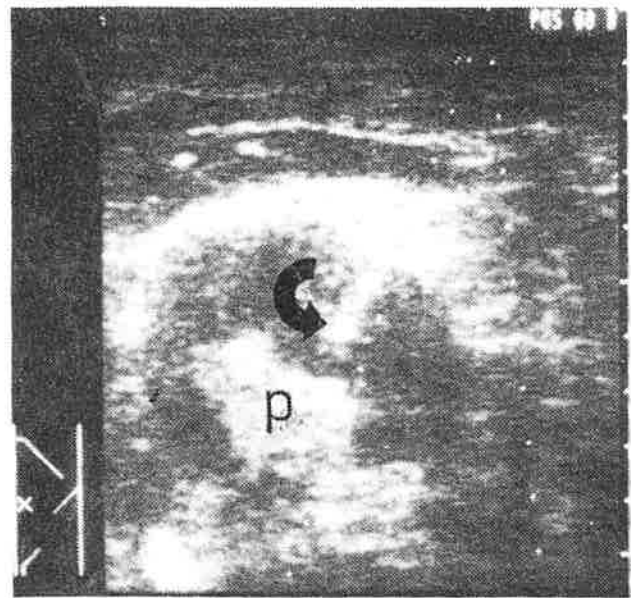


Fig. 2 – Semioblique linear feature of the left kidney during gentamycin application; hyperechogenic echoes of the pyelon (p), arrow shows the tip of the needle

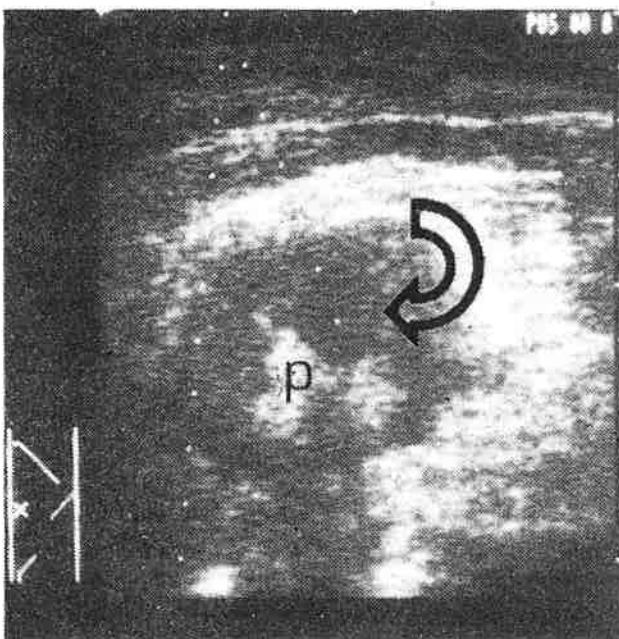


Fig. 3 – Semioblique linear scan of the left kidney after gentamycin application: hyperechogenic area caused by liquid antibiotic with microbubbles (arrow), pyelonic echoes (p)

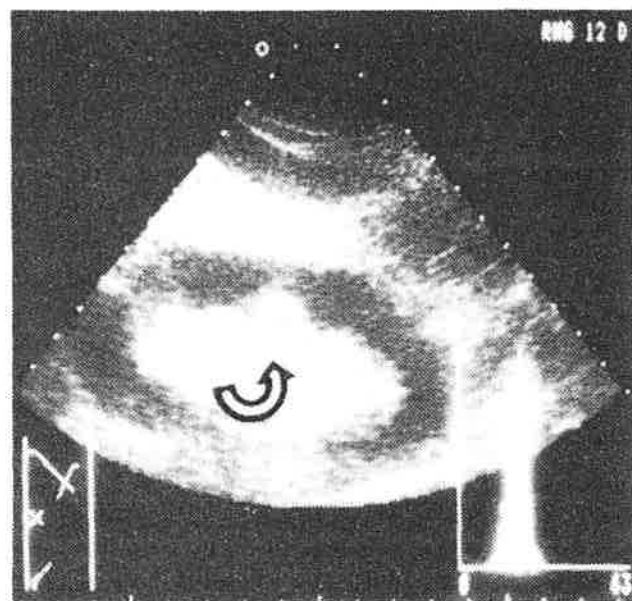


Fig. 4 – Intercostal sector scan of the left kidney after therapy; hyperechogenic area in the medial part of renal parenchyma (arrow) caused by fibrosis after inflammatory process healing, with histogram

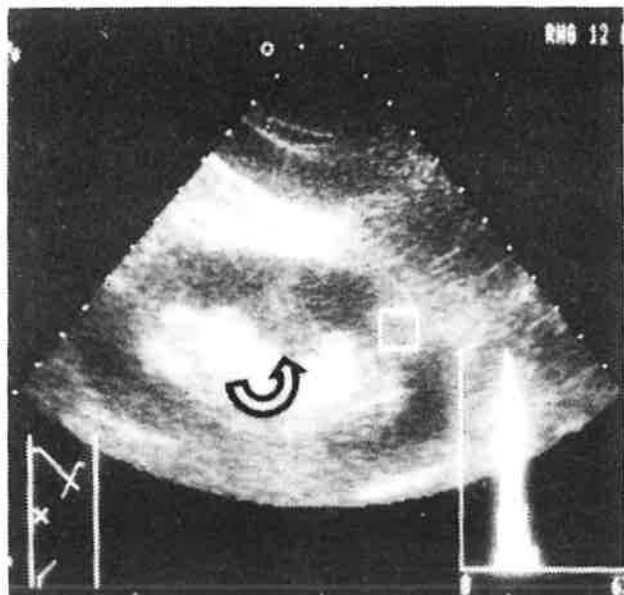


Fig. 5 – The same scan as in Fig. 4; arrow shows a clear hyperechogenic region; histogram was taken from normal surrounding renal parenchyma (note the various curves and numbers)

flank, upper part of the abdomen was bolstered for better kidney fixation. Sterilisation and confining of the operative field was done with standard solution and sterile compresses. With a sterilised ultrasound probe of 3.5 MHz the best position for puncture was fixed which meant that there was enough »protecting stratum« of healthy parenchyma between the lesion and renal capsule to prevent the possibility of bacterial propagation into the perirenal compartment. Skin incision (2-3 mm) was done under local anaesthesia. Pathological process as set in the position which corresponded to puncture-line of the probe. Following puncture-line, a thick needle was stung through the lumbar muscles. It served as a canal for a thin aspiration needle with aspiration biopsy of focal kidney lesion was performed 4-5 times under the negative pressure. Cytologic specimen was prepared in standard way.

The cytologic specimen showed dense mass of mature WBC and some macrophages.

After sonographic and cytological confirmation, a therapy was started as follows: four times, every 3-4 days, gentamycin (80 mg) was applied into the focal kidney lesion under ultrasound guidance. Application procedure was the same as described previously. Antibiotic was injected directly »in loco« with a syringe through needle along the guideline (Fig 2 and 3).

With the therapeutic procedure described, the regression of focal kidney lesion was complete and the patient was discharged with recom-

mendations for home care. Ultrasound follow-up examination after 3 weeks did not show presence of residual disease. Hyperechogenic area and its histogram analysis corresponded to fibrosis (Fig. 4 and 5).

Discussion – It noninvasiveness, painlessness, the possibility of repetition without consequences to the patients health and accuracy of diagnosis render ultrasonography the method of choice in the detection of kidney pathology. Interventional ultrasonography, enabling visualisation of diagnostic or therapeutic procedures (biopsy, nephrostomy, puncture and cyst sclerostation, application of various drugs), represents an advantage which further promotes the applicability of ultrasound. Histogram analysis of focal lesions, which is being investigated, facilitates the distinction between »pathological« and »normal«. Lobar nephronia is a localised form of pyelonephritis (2, 6, 9, 10) and is to be understood as the midpoint in a spectrum of pyelonephritis from acute pyelonephritis to abscess (6). Pathophysiologically a pronounced cortical vasoconstriction was localised in the areas of acute inflammation with clogging of the peritubular capillaries by inflammatory cells. After a few days this areas progressed to necrosis and/or abscess (10). This examination confirmed the thesis of lobar nephronia as a precursor of renal abscess.

Ultrasonography, i.v. urography and computerised tomography are the techniques used in the diagnosis of acute renal diseases. As the lobar nephronia comprises a spectrum of different pathological conditions with equal features the cytological puncture is necessary. The maturation of inflammatory process changes the sonographic image (enhancement of border echoes, separation from surrounding tissue). Liquefaction results in central hypo- or anechogeneity (1). Intravenous urography presents a solid expansive process and CT shows a wedge shape area of decreased attenuation (2). Although hypoechogenic area without increased posterior ultrasound beam enhancement is the most commonly described ultrasonographic findings in the recent literature (1, 2, 6, 9, 11), our patient had a slightly hyperechogenic solid mass, and therefore ultrasound diagnosis was implemented by sonographically guided puncture.

In the recent literature, classic parenteral antibiotic therapy is described as therapeutic procedure (2, 6, 11, 12). We decided for an intermittent topical antibiotic application with ultrasonical following of focal lesion regression.

Considering the previously mentioned advantages, complete regression was achieved after two weeks.

Conclusion – We presented a case of lobar nephronia. The disease was verified after ultrasonically guided puncture. We decided for a topical antibiotic application under ultrasonic control as a therapeutic procedure which proved to be successful. We believe that the described ultrasonically guided diagnostic and therapeutic procedures can be helpful in the treatment of some focal infections of the renal parenchyma. However, when making selection between classic therapy and that described in our report, appropriate education and experience of the physician should be of decisive importance.

Sažetak

SONOGRAFSKI VOĐENA PERKUTANA TERAPIJA LOBARNE NEFRONIJE

Prikazan je pacijent u kojeg je, na osnovu anamneze, statusa, laboratorijskih nalaza i ultrazvučnog pregleda postavljena sumnja na lobarnu nefroniju (akutni fokalni bakterijski nefritis). Izvršena je punkcija pod kontrolom ultrazvuka, te je citološki nalaz punktata potvrdio dijagnozu. U cilju terapije instiliran je u četiri navrata pod vodstvom ultrazvuka, »in loco«, Gentamicin (po 80 mg), što dovodi do potpune regresije fokalne lezije.

References

1. Fučkar Ž. Sonografija urogenitalnog sustava. Ljubljana–Rijeka: Partizanska knjiga, 1987.

2. Rosenfield AT, Glickman MG, Taylor KJW, Crade M, Hodson J. Acute focal bacterial nephritis (acute lobar nephronia). *Radiol* 1979; 132:553-61.

3. Hadžić N, Radonić M, Vrhovac B, Vucelić B. Priručnik interne medicine (dijagnostika i terapija). 3.1zd. Zagreb: Školska knjiga, Jumena, 1989;374.

4. Sharma SK, Kumar A, Sharma BK, Malik N, Fadnis P. International gas abscess. *J Urol* 1986; 136:1059-60.

5. Fučkar Ž. Interventni ultrazvuk. In: Kurjak A et al eds. *Ultrazvuk u kliničkoj medicini*. Zagreb: Medicinska naklada, 1989:515-63.

6. Morehouse HT, Eeiner SN, Hoffman JC—Imaging in Inflammatory Disease of the Kidney. *AJR* 1984;143:135-41.

7. Šustić A. Prilog interventnoj sonografiji bubrega. Rijeka: Medicinski fakultet Rijeka, 1989. Diplomski rad.

8. Godeck CJ, Tsai SH, Smith SJ, Cass AS. Diagnostic strategy in evaluation of renal abscess. *Urology* 1981;18:535-41.

9. Lee JKT, McClennan BL, Melson GL, Stanley RJ. Acute focal bacterial nephritis: emphasis on gray scale sonography and computed tomography. *AJR* 1980;135:87-92.

10. Hill GS, Clark RL. A comparative angiographic, micro-angiographic, and histologic study of experimental pyelonephritis. *Invest Radiol* 1972;7:33-47.

11. Funston MR, Fisher KR, Van Blerk JP, Bortz JH. Acute focal bacterial nephritis or renal abscess: a sonographic diagnosis. *Br J Radiol* 1982;54:461-6.

12. Siegel MJ, Glasier CM. Acute bacterial nephritis in children: significance of ureteral reflux. *ARK* 1981;137:257-60.

Author's address: Željko Fučkar, MD, Ph D, Ass. Prof., Clinic for Surgery, Urologic Department, Clinical Hospital Center Rijeka, 51 000 Rijeka