

RECONSTRUCTIVE MICROSURGERY

Cvrtak, Sara

Master's thesis / Diplomski rad

2024

Degree Grantor / Ustanova koja je dodijelila akademski / stručni stupanj: **University of Rijeka, Faculty of Medicine / Sveučilište u Rijeci, Medicinski fakultet**

Permanent link / Trajna poveznica: <https://um.nsk.hr/um:nbn:hr:184:854499>

Rights / Prava: [In copyright](#)/[Zaštićeno autorskim pravom.](#)

Download date / Datum preuzimanja: **2025-03-24**



Repository / Repozitorij:

[Repository of the University of Rijeka, Faculty of Medicine - FMRI Repository](#)





medri

**UNIVERSITY OF RIJEKA
FACULTY OF MEDICINE**

**UNIVERSITY INTEGRATED UNDERGRADUATE AND GRADUATE STUDY OF
MEDICINE IN ENGLISH LANGUAGE**

Sara Cvrtak

RECONSTRUCTIVE MICROSURGERY

GRADUATION THESIS

Rijeka, 2024



medri

**UNIVERSITY OF RIJEKA
FACULTY OF MEDICINE**

**UNIVERSITY INTEGRATED UNDERGRADUATE AND GRADUATE STUDY OF
MEDICINE IN ENGLISH LANGUAGE**

Sara Cvrtak

RECONSTRUCTIVE MICROSURGERY

GRADUATION THESIS

Rijeka, 2024

Thesis mentor: (Aleksandra Pirjavec Mahić, MD, PhD, Associate Professor)

The graduation thesis was graded on 12.06.2024 in Rijeka, before the Committee composed of the following members:

1. Damir Grebić, MD, PhD, Assistant Professor (Committee Head)
2. Harry Grbas, MD, PhD, Associate Professor
3. Marko Zelić, MD, PhD, Associate Professor

The graduation thesis contains 54 pages, 4 figures, 2 tables, 42 references.

Table of Contents

1. INTRODUCTION	1
2. AIMS & OBJECTIVES	1
3. LITERATURE REVIEW - RECONSTRUCTIVE MICROSURGERY	2
3.1. EQUIPMENT.....	3
3.2. MICROVASCULAR SURGERY	6
3.3. MICRONEURAL SURGERY.....	10
3.4. REPLANTATION SURGERY.....	14
3.4.1. Limb replantation.....	15
3.4.2 Digital replantation	21
3.4.3 Miscellous tissue replantation.....	24
3.5. FREE TISSUE TRANSFER (DONOR TISSUE)	25
3.5.1. Head and neck.....	29
3.5.2. Trunk	31
3.5.3. Upper limb	32
3.5.4. Lower limb	33
3.5.5. Foot	35
3.5.6. Toe transfer	36
3.5.7. Abdominal cavity.....	37
3.5.8. Vascularized bone grafts	38
3.6. MICROSURGICAL RECONSTRUCTION.....	39
3.6.1. Upper limb	39
3.6.2. Lower limb	40
3.6.3. Trunk	41
3.6.4. Head and neck.....	42
3.6.5. Lymphatic system	43
3.6.6. Urogenital system	44
3.7. RECONSTRUCTIVE MICROSURGERY TODAY.....	45
4. DISCUSSION	46
5. CONCLUSION	47

6. SUMMARY	49
7. REFERENCES	50
8. CV	54

LIST OF ABBREVIATIONS AND ACRONYMS

DIP - distal interphalangeal

FDS - flexor digitorum superficialis

LVLA- lymphatic-venous-lymphatic

MP - metacarpophalangeal

PIP - proximal interphalangeal

TTL - through-the-lens

1. INTRODUCTION

Reconstructive microsurgery is a highly specialized field that has significantly transformed modern medical practices. Utilizing advanced surgical microscopes and precision instruments allows surgeons to perform intricate procedures on small anatomical structures such as blood vessels and nerves, essential for the successful repair and reattachment of damaged tissues. Originating in the early 1960s with pioneering vascular anastomoses, this field has evolved dramatically, laying the foundation for the sophisticated techniques used today.

Microsurgical techniques have revolutionized plastic and orthopedic surgery by enabling the restoration of function and form in patients affected by severe trauma, congenital anomalies, or oncological resections. This field encompasses a wide range of procedures, including limb and digit replantation, free tissue transfers, and the repair of complex head, neck, and extremity injuries. The advent of super-microsurgery, which works with vessels as small as 0.1 mm, has further expanded therapeutic options, particularly for conditions like lymphedema.

Beyond its technical advancements, reconstructive microsurgery represents a paradigm shift in surgical philosophy, emphasizing meticulous precision and innovative problem solving. The evolution of this field has led to significant improvements in surgical techniques, postoperative care, and rehabilitation protocols, enhancing patient outcomes and quality of life. By enabling complex reconstructions and tissue repairs, microsurgery has opened new frontiers in medical treatment and patient care.

This thesis explores the capabilities and impact of reconstructive microsurgery, examining essential equipment, techniques such as microvascular and microneural surgery, and their diverse applications. Through a comprehensive examination, it highlights the critical role of microsurgery in advancing medical care and improving patient outcomes, underscoring its indispensable contribution to modern medicine.

2. AIMS & OBJECTIVES

The primary aim of this thesis is to provide a comprehensive exploration of reconstructive microsurgery, focusing on its advanced techniques, diverse applications, and the significant impact it has on patient outcomes in modern medical practices.

This thesis will detail the fundamental techniques of reconstructive microsurgery, such as microvascular and microneural procedures, and discuss the specialized equipment and instruments essential for performing these intricate surgeries. By illustrating their critical role in enabling precise and effective surgical interventions, the thesis aims to highlight the importance of these techniques.

Furthermore, the clinical applications of reconstructive microsurgery will be explored, with a focus on its use in various anatomical regions, including the head, neck, and extremities.

The thesis will also review recent advancements in microsurgical methods and technologies, such as the development of super-microsurgery, and evaluate their impact on surgical outcomes and patient care. By examining these innovations, the thesis will highlight the continuous progress and expanding therapeutic options in the field.

Postoperative care and rehabilitation strategies that support successful recovery following microsurgical procedures will be discussed, emphasizing the importance of multidisciplinary approaches in optimizing patient outcomes. This section will address the comprehensive care required to ensure the best possible recovery and quality of life for patients.

Finally, the thesis will outline potential future developments in reconstructive microsurgery, addressing current challenges and limitations within the field. By proposing areas for further research and improvement, the thesis aims to contribute to the ongoing advancement of microsurgical practices.

Through these aims and objectives, this thesis seeks to provide a detailed and insightful overview of reconstructive microsurgery, demonstrating its indispensable role in modern medical treatment and its profound impact on patient care.

3. LITERATURE REVIEW - RECONSTRUCTIVE MICROSURGERY

Microsurgery is a sophisticated field of surgery that has been integrated into various medical specialties, profoundly transforming modern surgical practices. It is extensively utilized in ophthalmology for procedures such as glaucoma treatment, cataract surgery, and corneal transplants. Additionally, microsurgery is pivotal in maxillofacial surgery, otolaryngology,

urology for reversing vasectomies, and gynecology for tubal ligations to address infertility issues (1). This discipline encompasses all surgeries that employ a surgical microscope as the primary tool, enabling surgeons to visualize structures smaller than 5 mm in diameter (2).

In the realm of reconstructive surgery, microsurgery plays a crucial role, especially within plastic and reconstructive surgery. Together with orthopedic surgeons, these specialists perform revascularization and nerve repair on damaged tissues, significantly aiding patients suffering from severe trauma, cancers, and congenital anomalies (3). The advent of microsurgery can be traced back to the early 1960s when vascular surgeon Jules Jacobson, at the University of Vermont, successfully used an operating microscope to anastomose vessels as small as 1.4 mm. This breakthrough paved the way for further advancements, leading to the development of super-microsurgery. Today, surgeons can work with vessels as minute as 0.1 mm, yielding promising results, particularly in the treatment of lymphedema (4). Through this thesis, we will delve into the intricate world of reconstructive microsurgery, exploring its remarkable capabilities and understanding the profound impact it has on modern medicine.

3.1. EQUIPMENT

This field of surgery requires special equipment that elevates surgeon's skills, which minimize trauma to small structures and make it possible to be repaired with precision (5).

Surgical loupes

Surgeons are first introduced to operating magnification through surgical loupes, which, in some cases, are even more practical than microscopes. They are flexible, easily portable and cheaper choice in comparison to microscopes. Loupes are essential for micro dissection, especially at the beginning of procedures, until greater precision is required. They are used when high magnification is unnecessary but improved technical precision is essential.

Typically, loupes offer fixed magnification between 2.5x and 5x. (5, 6)

Loupes are categorized into three groups: simple, compound/Galilean, and prismatic. Simple loupes, made of a single meniscus lens, are primitive magnifiers with limited capabilities and are not widely marketed due to the superior performance of the other types. Compound/Galilean loupes, the foremost common sort, comprise of two magnifying lenses

isolated from one another, advertising more noteworthy magnification, profundity of field, and longer working distances.

Prismatic loupes include a more complex optical framework, giving indeed higher magnification and longer working distances compared to compound loupes.

Additionally, loupes are classified based on their attachment to glasses: through-the-lens (TTL) and flip-up loupes. TTL loupes are custom-made, adjusted to the surgeons' interpupillary distance, and situated at a steep declination point for client consolation. Flip-up loupes allow the magnifying lenses to be moved up or down as needed during procedures, are not customized to a single user, and are cheaper than TTL loupes. However, flip-up loupes offer a narrower field of view due to the lens's proximity to the user's eye.

Loupes can too be prepared with a light source connected by a cable to a battery situated within the surgeon's pocket. Despite their advantages, loupes are less popular nowadays due to poor ergonomics, requiring a fixed distance between lenses that makes it difficult for the operator to find a comfortable position, often leading to neck and back fatigue (6).

Surgical microscope

In any surgical situation requiring precise recognition of small tissues or structures, the surgical microscope significantly enhances outcomes. It is indispensable when operating on structures 3 mm or less in diameter (5). This "star of the show" combines the magnification power of loupes with a magnification changer and a binocular viewing system, providing stereoscopic vision for in-depth orientation. Unlike with loupes, posture issues are mitigated as the surgeon can sit upright. The working distance for using a microscope typically ranges from 200 to 400 mm, allowing for simultaneous use of the microscope and surgical instruments. Most importantly, the microscope offers adjustable magnification from 1.5x to 30x, maintaining focus and high image quality throughout the range.

The main components of an operating microscope include binocular tubes, a variation system, lenses, coaxial field lighting, a camera, and a pedal. The binocular tubes are mobile, allowing individual adjustment to the user's interpupillary distance and diopter settings. They are usually tiltable up to 180 degrees for better ergonomics and provide magnification typically between 10x and 12.5x. Most systems include two sets of binocular tubes, enabling two surgeons to operate together.

The variation system provides adjustable zoom, allowing the surgeon to switch easily between low and high magnification as needed. The lenses are crucial for image quality, with focal lengths ranging from 100 to 400 mm. Surgical microscopes use coaxial field lighting, commonly halogen or xenon, to illuminate the surgical area.

Cameras are essential for recording procedures and capturing images for follow-up. In some cases, an infrared camera is utilized with Indocyanine Green contrast to better assess the lymphatic system or perform intraoperative angiography. The pedal permits the surgeon to adjust the focus area and capture videos or images without using their hands (6).

3d heads-up microscopy and exoscopes

Innovative technologies like 3D heads-up microscopes are now being used during operations, enhancing the comfort of the microsurgeon by allowing them to sit straight with their heads up. This reduces the likelihood of musculoskeletal fatigue while maintaining image quality and technical accuracy (7). While exoscopes are more commonly used in neurosurgery, particularly for spine operations, they give a high-resolution picture of the surgical field from a computerized camera framework onto a 2D or 3D high-resolution screen (6).

Instruments and sutures

Instruments are critical in microsurgery and must meet specific requirements to ensure precision and effectiveness. They need to be designed specifically for microsurgery and be of high quality. A satin finish on instruments is necessary to prevent glare under the microscope, which could distract the surgeon. Additionally, instruments must be long enough to allow the operator to keep their hands in a resting position.

A microsurgical set typically includes a microneedle holder, straight and curved Dumont forceps, vasodilator forceps, microscissors, clamps, a microvascular clamp applicator, and thin sutures. Spring-loaded needle holders are approximately 15 cm long and rest between the index finger and thumb. These holders can have a round or flat grasp on the handle, with tips that can be curved, angled, or straight, and fine enough to hold the needle without misshaping its bend. They should have thin jaws with thin shoulders capable of grasping and tying sutures as thin as 10 μm .

Microsurgical forceps numbered 2, 3, and 5 are highly effective for microsurgery. The tips should be fine, smooth, uniform, and coincide evenly over a length of 2 mm, making them

capable of handling 10/0 and 11/0 nylon thread without causing damage. Vasodilator forceps are inserted into the end of a vessel, that was cut, and have to be rounded and polished tips to provide counter pressure while suturing delicately.

Microscissors feature a spring handle, with curved or straight blades that could be short or long, depending on the surgeon's requirements. The tips are rounded to prevent damage to the tissue around the vessel. Additionally, adventitia scissors have straight and sharp blades for removing adventitia from vessels or removing sutures.

Microvascular clamps should be well designed, small, and lightweight to perform successful anastomoses. They are used to obstruct blood flow and must be carefully selected based on the vessel size. Clamp applicator forceps are planned for appropriate dealing with of microvascular clamps.

Sutures in microsurgery are crucial, and selecting the right material is essential for optimal results. Sutures need to be inert, antithrombotic, and preferably colored for visibility under the microscope. Nonabsorbable synthetic monofilaments are preferred, with nylon being commonly used due to its strength and favorable black color for better visibility.

Polypropylene and polyester monofilaments are also used; however, they are softer than nylon and usually light-colored, making them harder to see and requiring more care. Suture sizes range from 8/0, 9/0, 10/0, to 11/0, with 12/0 and 13/0 used in supermicrosurgery.

Needles used in microsurgery are chosen based on the specific surgical situation. Important factors include needle length, needle profile (usually 3/8), needle breadth measured in microns, and needle cross-section, which ordinarily highlights an atraumatic tip and round body (5, 6).

3.2. MICROVASCULAR SURGERY

Microvascular techniques are fundamental skills required for anyone aspiring to practice reconstructive microsurgery, or microsurgery in general. This specialized knowledge demands hours of patient practice in the laboratory before a surgeon can operate on a human. It requires exceptional skills and extreme concentration to avoid complications and to be prepared for logical decision-making in unexpected situations.

Every surgeon embarking on this journey to become a microsurgeon must first and foremost understand the fragility of the tissues they are handling. The importance of meticulous care in handling these small vessels visible under the microscope cannot be overstated. In practice, it has been determined that a surgeon needs to achieve at least a 90% success rate in experimental repairs of 1 mm diameter vessels before attempting clinical anastomoses.

Handling of tissue

As mentioned earlier, understanding the basics of anatomy, particularly the differences between arteries and veins, is essential before beginning to perform sutures. Arteries can handle more pressure and manipulation than veins due to having fewer collagen fibers in their walls. This makes the free edges of veins, which need anastomoses, more collapsible and easily damaged.

Given that the main focus of this thesis is reconstruction, it is crucial to emphasize that patients often present with damaged tissue requiring repair. Under the microscope, all vessels must be carefully inspected for any signs of damage that need debridement. In damaged tissue, vessels are likely to be in a state of spasm. This can also occur in non-traumatized tissue if the room temperature is low, there is suboptimal perfusion, light anesthesia, dryness, rough handling, or underlying vascular disease.

In these cases, where vessels are normal, we gently dilate the vessel with forceps and apply Xylocaine 2% or verapamil combined with moist gauze coverage. The same approach applies to abnormal vessels after resecting until normal vessel tissue is reached. Ignoring any abnormalities can lead to thrombosis, which can also occur if the subsequent anastomosis is poorly managed, with bad technique, torsion of the vascular pedicle, or prolonged ischemic time.

Thrombosis is a significant issue in cases of poorly performed adventitiectomy of the vessel end. The adventitia can disrupt laminar blood flow, leading to thrombin accumulation if it extends into the lumen of the vessel.

It is also vital to highlight that in some cases, where the size of the vessels needs to be adjusted for joining, a dilator forceps is required to widen the vessel lumen. Care must be taken during this process, as over-dilation can harm the vascular endothelium. (5, 6, 8)

End-to-End anastomosis

The most commonly used anastomosis technique involves suturing one end of a vessel to another. Various methods can be selected based on the surgeon's skills, the vessel's lumen diameter, and its tendency to collapse. Before deciding on a technique, blunt dissection is performed to expose the vessels requiring anastomosis. This is followed by isolating the arteries and veins from each other and ligating the branches using bipolar electrocautery. Once the vessels are uncovered and cut, heparinized saline solution is utilized to wash out the vessel lumens to avoid thrombosis. A twofold clamp is used to approach both edges of the vessels, and a contrasting background is applied for better visibility. A double clamp is used to approach both edges of the vessels, and a contrasting background is applied for better visibility. Before using a blunt dilator to dilate the vessel, the adventitia must be trimmed with forceps and microsurgical scissors to avoid complications.

Halving 180° or "The 180° technique" or biangulation technique is most frequent for end-to-end anastomoses. It describes the placing of the stiches in a way we stich two interrupted sutures at 180° angle. Surgeons usually use the representation of a clock to have a better picture of stich placement. First two stiches are put on 12 o'clock and 6 o'clock positions. At that point stiches at 3 o'clock, 1o'clock and 4 o'clock are placed, where middle stich is left the longest since of way better vessel handling by dodging suturing the back wall of the vessel. After this the double clamp is flipped for 180° for exposure of posterior wall where you complete the anastomoses after checking the lumen and reapplying the heparinized saline solution. Afterward, the remained sutures are released, and the clamp is removed. Placing the fat tissue and cloth over the new anastomoses is a step before we check the potency after few minutes. If the bleeding occurs after this step the additional stiches may be needed to finish the anastomosis.

The triangulation technique, rarely used in microsurgery, is mainly for anastomosing larger vessels or reducing the risk of accidentally including the opposite wall in small vessels. It involves initially placing three sutures 120° apart on the vessel's circumference, creating three small segments of the circle, which are then sequentially sutured (Figure 1.).

The "back wall up" or "back-wall-first" technique is used for very delicate vessels that cannot be rotated. In this method, the first suture is placed in the middle of the back wall, with subsequent sutures progressively added forward on each side. (8, 9)

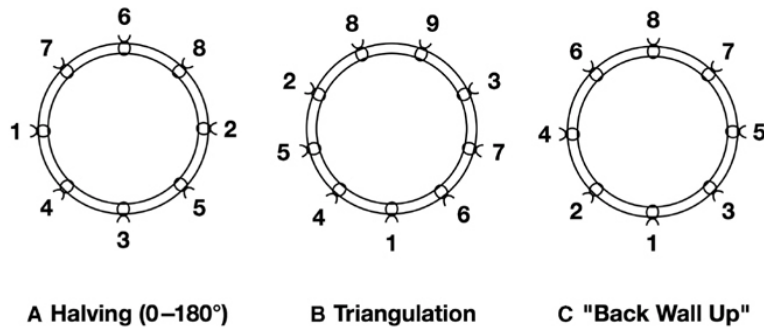


Figure 1: Techniques used in forming end-to-end anastomoses with order of the stitches applied: A- Halving, B- Triangulation, C- Back-wall-up/Back-wall-first

End-to-Side anastomoses

Reconstructive microsurgery involves the intricate task of free transferring composite tissue using microvascular anastomoses, a procedure crucial for restoring form and function in various medical scenarios. Typically, recipient vessels with diameters ranging from 1 to 2mm are prepared for a free flap by employing end-to-end anastomoses. However, in cases where such vessels are not readily available, particularly in the lower limb where sacrificing a large vessel could disrupt distal blood flow, alternative techniques become imperative.

On the face, where vascularized tissue is abundant, this is less of a concern. Conversely, in the lower limb, sacrificing a major vessel can lead to significant distal blood flow disturbances. To address this challenge, the end-to-side procedure is regularly utilized to preserve adequate blood circulation within the distal region or organ.

This technique begins with the careful placement of three temporary clips on the vessels: one on the donor end and two on each side of the recipient vessel. Prior to anastomosis, the donor vessel's end is cut at a 30-degree angle, while the recipient vessel requires arteriotomy, creating an elliptical opening using a no.11 surgical blade.

The first suture is meticulously placed near the proximal end of the donor vessel, aligned with longitudinal angle of the elliptical opening on the recipient vessel. Subsequently, the second suture is put on the opposite side, followed by circumferential sutures. Notably, the needle always traverses from the vessel's outside into the lumen, ensuring that the knot resides outside of the vessel. Additionally, between transitions from the posterior to the anterior wall, flushing the lumen with heparinized saline is essential to prevent clot formation.

Upon completion of the anastomosis, the clips are sequentially removed, starting from the vessel with the lowest blood pressure to the highest. The procedure culminates in a meticulous inspection for any signs of potential bleeding, ensuring the successful restoration of blood flow to the targeted region or organ. (8, 9)

Vessel grafts

In certain scenarios, such as during digit replantation, free flap procedures, or toe-to-hand transfers, challenges may arise due to vessel size discrepancies or other deficiencies. One common method employed to address such issues is the use of vessel grafts, typically involving the addition of a vein graft to an artery.

This technique necessitates meticulous preparation of both the artery and vein, followed by microsuturing using the methods mentioned earlier. To begin, the artery is clamped and irrigated with heparinized saline. The adventitia is then carefully trimmed, and the artery is dilated using vasodilator forceps. Measurement of the length between the ends of the artery helps in determining the required size of the graft.

Conversely, preparation of the vein involves ligating all possible branches and checking for leaks via hydro-distention. When inserting the vein graft into the artery, it must be reversed. It's crucial to ensure that the ends of the vein are ligated and that there is an additional 1mm of length beyond the defective artery on each end. After excising the first end, irrigation with heparinized saline is necessary before the adventitia trimming and excising the other end, readying it for suturing.

The suturing process typically involves employing the biangulate technique, ensuring that the vein is not twisted during the procedure. This meticulous approach is fundamental to guarantee the successful integration of the graft and to avoid any complications that may emerge from vascular misalignment or obstruction. (5, 6, 8, 9, 10, 12)

3.3. MICRONEURAL SURGERY

Nerve repair is indicated in many situations, including loss of sensation after traumatic injury, paralysis following a wound, surgery, injection, or closed injury, certain nerve lesions, failure

of recovery after a previous nerve repair surgery attempt, and treatment of painful neuroma. Trauma or injury, the most common reason for a reconstructive surgeon to perform this kind of surgery, necessitates the consideration of several factors that significantly influence recovery outcomes.

The level of injury plays a crucial role in the end result. More proximal injuries are more likely to result in distal tubal collapse, scarring, and end organ degeneration before axons reach their destination during regeneration. The type of injured nerve is also an important factor, as pure motor or sensory nerves are more likely to regenerate than mixed nerves. The extent of the injury is another critical consideration; clean cuts tend to result in better recovery compared to traction, avulsion, or crushing injuries, where the damage is more internal, increasing the likelihood of nerve tissue loss.

Additionally, associated tissue damage can enormously impact the seriousness of the nerve damage. Harm to the vessels providing the nerve or skin loss can lead to devascularization and eventual ischemic damage. Severe local soft tissue damage and subsequent scarring can also significantly impact the direction of axon regeneration.

Surgeons often rely on the Mackinnon classification of nerve injury when deciding the suitability of an operation, with only injuries classified as VI and above being candidates for surgery. (Figure 2)

Degree of injury	Tinel's sign present	Recovery	Rate of recovery	Surgical procedure
I Neurapraxia	No	Complete	Up to 12 weeks	None
II Axonotmesis	Yes	Complete	1* per month	None
III	Yes	Varies*	1* per month	None or neurolysis
IV Neuroma in continuity	Yes, but no advancement	None	None	Nerve repair, graft, or transfer
V Neurotmesis	Yes, but no advancement	None	None	Nerve repair, graft, or transfer
VI Mixed injury (I-V)	Some fascicles (II, III)	Some fascicles (II, III)	Depends on degree of injury (I-V)	Neurolysis, nerve repair, graft, or transfer

*Recovery can vary from excellent to poor depending on the amount of scarring and the sensory versus motor axon misdirection to target receptors.

Figure 2: Mackinnon classification of nerve injury

Besides the injury, the patient's age (with the best results seen in children), timing of repair, and technique of repair are factors that can influence the healing process. Regarding the timing of repair, it is divided into primary and secondary repair. Primary repair is the best

choice for optimal outcomes. Waiting for nerve repair can lead to retraction of nerve endings, making end-to-end nerve anastomoses very difficult and increasing the need for nerve grafting. Secondary nerve repair is a better choice when an infection is present, making immediate surgery impossible. In this situation, the only advantage is that the scarred proximal limit of nerve damage can be easily seen under magnification. (5, 6, 10, 17, 18)

Techniques in Nerve Repair

The surgical goal for the microsurgeon is to eradicate the damaged nerve and realign the proximal and distal nerve fascicles with the correct orientation and tension at the nerve junction suture. As the results of nerve repair surgery become visible over a longer period (approximately 4 to 6 weeks), unlike in vessels, surgeons must perform the best possible job in hopes of a positive outcome.

First, it is crucial to ensure adequate exposure of the nerve endings under magnification. The surgeon needs to visualize the filmy adventitial layer, which is continuous with the mesentery on the deep surface of the nerve. This adventitia is resected from the nerve endings for 5 mm. It should not be mistaken for the rubbery epineurium, as it is an important layer that maintains the general topography of the nerve bundles. During this procedure, only the connective tissue (epineurium and perineurium) is used to manipulate the nerve.

When the nerves are prepared, the procedure can proceed using two different techniques based on the end-to-end principle anastomoses.

The first option is a technique used only in nerves where afferent or efferent bundles are present, known as epineural nerve coaptations, where the operator sutures only the epineurium. Typically, 4 to 6 stitches are needed for this technique because the stitches are not applied for mechanical estimation of the nerve edges, as in vessels, but only as guidance for growth of axons.

For a more precise match of each fascicle in nerves holding afferent and efferent fascicles, perineural and epiperineural nerve adjustment techniques are employed. In perineural coaptation, the surgeon carefully mobilizes each fascicle from the epineurium and places sutures only in the perineurium. Two opposite knots are placed for each fascicle. Pre-matching of fascicles is crucial for this technique.

The epiperineural suture technique combines both epineural and perineural coaptation. It is a method to perfectly match the nerve fascicles by suturing both the epineurium and perineurium. This difficult procedure requires significant attention and care. For better orientation, the microsurgeon usually uses the vasa nervorum as a guide to match the complex pattern of the nerve. The process begins with the lowest fascicle and continues circumferentially.

As in microvascular surgery, the end-to-side technique can also be applied to nerves. It has been used for many peripheral nerve reconstructions, especially in brachial plexus or facial nerve lesions, as well as for avoidance of pathological neuromas. Main mechanism that facilitates this process is axonal sprouting, where fine nerve processes grow out from the local axon to innervate nearby muscle fibers and reestablish innervation. During this process, it is necessary for the operator to distinguish between the epineurium and perineurium, often using dyes. Using sharp pointed scissors, a tiny hole is created in the epineurium of the recipient nerve, and by selecting and mobilizing the fascicle; a graft is sutured to the donor nerve using an epineural suture. (6, 10, 17, 18)

Nerve Grafting

Nerve grafting becomes necessary wherever a nerve gap is present, which may result from the loss of nerve substance or due to secondary retraction without any nerve loss. It is usually employed in situations where additional length is required for nerve transfer, such as in cross-facial nerve grafts, neurotization of the brachial plexus by intercostal nerves, or direct muscle neurotization.

The best graft in these situations is always a fresh autograft, with sensory nerves being the most commonly used grafts. Typical donor nerves incorporate the sural nerve, the medial cutaneous nerve of the forearm, and the lateral cutaneous nerve of the forearm.

The sural nerve offers the greatest length, up to 35 cm, with minimal morbidity. Its diameter is sufficient to match nerve deficiencies and to allow rapid revascularization from the graft bed. Harvesting this nerve involves creating a small longitudinal incision behind the lateral malleolus of the ankle, where the short saphenous vein accompanies it. Four to five additional small transverse incisions are made over the nerve's course to trace it to the popliteal fossa.

The medial cutaneous nerve of the forearm is used in grafting for hand and forearm surgeries. It is located between the axillary artery and vein, descending from the brachial plexus. After

piercing the deep fascia, it divides into two branches, and any part of this 20 cm nerve can be used for grafting.

The lateral cutaneous nerve of the forearm is a terminal branch of the musculocutaneous nerve, descending along the radial border of the forearm after passing deep to the cephalic vein. It is used more in digital nerve defects due to its fascicular similarity with the nerves in that area.

Nerves are avascular and require revascularization to function as grafts, so a flap cover must be performed first to create a graft bed. Once this is completed, the nerve graft procedure can proceed by trimming both nerve ends and suturing them loosely with 1 or 2 sutures of 10-0 nylon to the selected group of fascicles at the recipient nerve ends.

Post-procedure, the patient must recover by immobilizing the joints in slight flexion for three weeks. If the nerve grafts are without tension, immobilization is required for only 10 days, followed by gradual physiotherapy. (5, 10)

3.4. REPLANTATION SURGERY

This type of surgery presents a significant emergency within the field. Because of its importance, techniques have been continuously improving since the 1960s. It is not only an aesthetic and functional matter but also a potentially life-threatening situation where significant blood loss can lead to hemorrhagic shock. In such cases, the patient's general condition needs to be thoroughly assessed.

In replantation surgery, the goal is to reattach lost tissue to its original location to enhance the patient's quality of life and functionality. Accidents that necessitate this surgery are common, particularly among those working with machinery in industrial environments or agriculture, as well as in car accidents.

Medical staff in the field has the critical responsibility of caring for the lost tissue and the injured part of the body, ensuring proper care until the patient reaches the operating room. This crucial first step can significantly impact the outcome of the procedure. (5, 6, 11, 12, 13)

3.4.1. Limb replantation

Limb amputations are fortunately still somewhat uncommon compared to digital amputations. This is fortunate because limb amputations result in a greater loss of tissue and larger vessels, making them more dangerous due to the potential for significant blood loss.

The decision to proceed with replantation surgery and its end results rely on many factors: the general condition of the patient (including other injuries, vascular diseases, and systemic diseases), age (replantation becomes progressively less favorable with increasing age), level of amputation (proximal amputations with greater muscle mass have significantly poorer outcomes compared to distal amputations with little or no muscle), surgeon's experience (shorter operating times have shown better results), and type of injury, which is the most influential factor. Injuries are divided into four groups: guillotine-type amputation, crush amputation with local tissue damage, crush amputation with extensive tissue damage, and avulsions. (5, 6, 11, 12)

Guillotine-type amputation has the most excellent survival rate and prognosis among all types. Minimal debridement is needed, and the clean cut makes the surgery easier, leading to great results.

Crush amputation with local tissue damage requires more extensive debridement, but the outcome is still very good because the debridement makes the injury resemble a guillotine-type amputation.

Crush amputation with extensive tissue damage is usually caused by high-energy blunt trauma, which leads to extensive tissue damage. The necessary extensive debridement makes the survival rate in this situation less favorable.

Avulsion amputations involve the tissue being torn off rather than cut off. This means that vessels, nerves, muscles, and tendons are usually torn, extending the damage further. Grafting at every level is usually necessary, along with radical removal of debris, making this type of amputation have the worst prognosis of them all. (5, 11, 14, 15)

First aid

At the accident site, all tissue must be found and preserved to consider the possibility of replanting several parts or the potential need for extra tissue during surgery. The amputated part should be placed in a sterile bag, then in a cooling box, and a photograph should be taken to show medical staff without repeatedly removing it from the box. A sterile dressing has to cover the stump, and no tourniquets should be applied. Transport should be as rapid as possible to ensure the operation can begin quickly, increasing the chances of tissue preservation.

The patient should be administered broad-spectrum antibiotics (such as penicillin and ampicillin), prophylactic tetanus measures, hemoglobin perfusion solution, and a possible blood transfusion if the blood loss is significant. (5)

Indications for replantation

In upper limb amputations, there are four primary indications for replantation surgery: amputation of the thumb, any amputation in children, multiple digit amputations, and amputations occurring at the level of the palm, wrist, and distal forearm. Other indications depend on factors (the patient's age, occupation, dominant hand, general health, and personal preferences). The surgeon must assess the injury to determine whether the potential outcome will justify the surgery or if the severity of the injury makes achieving functionality unlikely. In lower limb amputations, replantation surgery is rarely performed due to the functionality and advancements in leg prostheses. Consequently, patients would seldom benefit from replantation in terms of improved quality of life. (5, 11, 14)

Anesthesia

The most favorable anesthesia used is long-acting regional anesthesia combined with intravenous sedatives. In children and restless patients, general anesthesia is preferred. (5)

Sequence of Replantation Procedure

Logically, we aim to reestablish circulation first, but this is only possible once the bone is fixed, using plates or Kirschner-wire fixation, to avoid anastomosis damage. If the vessel tissue is destroyed, vein grafts, usually taken from the saphenous vein due to its length, are needed. Muscle repair follows, with larger muscles being more urgent to rejoin due to their tendency to degrade without blood supply. After vessel anastomosis, nerve repair is performed,

typically using the epineural technique. In some cases, interfascicular suturing has shown better results if time allows. Once these steps are completed, the wound is closed, and we can address the exterior and any necessary skin grafts.

It is important to note that the usual number of operating teams is two—one for the amputated part and another for the stump. The importance of time and the need for a quick and precise procedure require as much assistance as possible. (5, 14)

Arm replantation

In comparison to digital and hand replantation, arm replantation is still relatively rare. The level of the amputation is crucial; the more proximal the amputation, the more complications arise and the worse the functional outcome. The abundant musculature in the arm makes it more susceptible to tissue anoxia. Muscles are particularly sensitive to blood loss, leading to irreversible tissue damage at temperatures between 20 to 25 degrees Celsius after only six hours.

Arm replantation takes a long time for nerves to regenerate, and rehabilitation is frequently unsatisfactory because of stiffness in the joints and muscle degeneration—this is especially the case for older patients or badly crushed arms. Candidates for replantation should be younger than 60 years old, have no other serious injuries, an amputated limb in good condition, and a willingness to undergo the exhausting postoperative recovery process. Because of the abundant muscle tissue at this level, the procedure requires massive debridement and rapid revascularization to prevent muscle destruction. During the procedure, arterial anastomosis is performed as soon as possible, typically immediately after bone fixation, to prevent lactic acid and toxic breakdown products from anaerobic metabolism from destroying the tissue. The bone ends are trimmed and fixated, followed by vein anastomosis and nerve anastomosis. The procedure is completed with dressing placement and splint immobilization. (5, 15)

Forearm replantation

For the arm, the greater amount of muscle tissue proximally increases the risk of irreversible ischemic changes. The only advantage of a proximal injury is that the larger vessels are more visible and easier to repair. Replantation is an option for every forearm amputation. A tourniquet is utilized during the proximal stump resection procedure. Similar to any other

replantation procedure, radical debridement is required. The ulnar, median, and radial nerves are marked, as are the ulnar and radial arteries and veins.

Kirschner wire fixation is then used for bone shortening and fixation. Nerve and vein anastomosis should usually be completed before artery repair. But arterial repair takes precedence if the ischemia period exceeds six hours. Prior to vessel anastomosis, muscles, tendons, and nerves should be sutured since the surgeon can work more quickly without having to deal with blood. At last, the skin is sealed, and a heavy bandage and dressing are placed on it. To lessen swelling, the upper limb is maintained at the level of the heart. (5, 11)

Hand replantation

Replantation surgery, like any other, commences with the meticulous process of debridement to remove necrotic tissue and any foreign bodies present. This is crucial for ensuring optimal conditions for successful graft survival. Following debridement, the focus shifts to bone preparation and stabilization, typically achieved using 2 to 3 Kirschner wires. Next, all of the tendons need to be repaired. Additionally, the flexor retinaculum ligament, which overlays the carpal tunnel, needs to be addressed to guarantee adequate adherence and tightening within the tunnel.


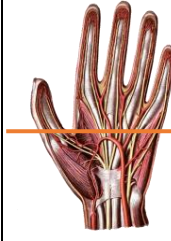
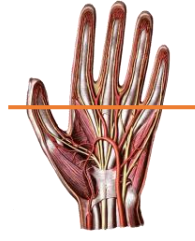
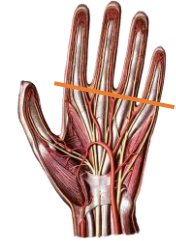
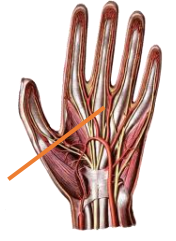
Identification and anastomosis of key veins, including the radial, ulnar, and the larger dorsal veins (4 to 5 in number), are performed in an interrupted fashion. Nerve repair is equally critical, with both the median and ulnar nerves addressed using the epineural technique. Additionally, repair of any superficial branches of the radial nerve is advocated to prevent the formation of painful neuromas in the future.

Given the intricate nature of the wrist anatomy, surgeons must possess a thorough understanding of its complexities. To determine which structures are injured depending on the level of hand amputation, even seasoned surgeons may use the Honda categorization (Table 1).

The level of injury dictates the precise approach to suturing, anastomosis, and fixation of structures. Moreover, the outcome of the procedure is intricately linked to the level of amputation. Specifically, Types B and C injuries often result in impaired thumb function, a crucial component of hand dexterity, as well as disrupted lateral pinch after the recovery period. Injuries occurring at the level of the carpal tunnel pose particular challenges, as this region houses the primary structures responsible for hand function and vascularization.

Consequently, recovery from such injuries may be complicated by impaired function in the long term. (5, 11, 12, 13, 14, 15, 17)

Table 1: Honda classification of types in hand amputations

Type of amputated hand	Type A	Type B	Type C	Type D	Type E
Level of amputation					
Level of bone amputation	Carpus	1-5 metacarpus	2-5 metacarpus	2-5 metacarpus	1-4 metacarpus
Artery	Radial and ulnar artery	Palmar arch	2-5 common digital artery, proper palmar digital artery, proper digital arteries of the thumb	Common digital artery	Common digital artery
Nerve	Ulnar, median, superficial radial nerve	Common digital nerve	2-5 common digital thumb or proper palmar digital nerve	Common digital nerve	Common digital nerve

Lower leg and foot replantation

There's a noticeable contrast in the abundance of literature on upper limb versus lower limb surgeries. This may be attributed to the fact that the decision to pursue replantation surgery is less common, given the advancements in prosthetic technology, which often offer superior functionality compared to reattached limbs. However, there's a more optimistic outlook when

the injury occurs at a lower level, especially in young patients. Conversely, avulsion-type injuries seldom yield successful outcomes, rendering replantation efforts less favorable in such cases.

In contrast, foot transplants typically follow a more conventional approach, involving bone fixation, nerve, vessel, and tendon repair, which can be relatively straightforward due to the alignment of these structures. When contemplating surgery, consideration of the extent of tissue damage and the necessity for bone trimming becomes paramount. This is crucial for maximizing functionality and reducing problems that can seriously affect a person's quality of life, like limping and difficulties carrying out regular tasks. (5, 11, 16, 17, 18, 19)

Postoperative management

Post-operation, meticulous care is administered to the replanted limb to promote successful healing and prevent complications. This includes the application of bulky dressings and bandages with careful attention to avoid compressing the anastomosed vessels.

Immobilization is ensured through the placement of a plaster cast, while elevation of the limb aids in reducing edema, with regular inspection of the fingertips to monitor for any signs of compromise.

Continuous monitoring of vital signs and skin temperature is maintained throughout the hospital stay, alongside regular assessment of hemoglobin and hematocrit levels. Thrombosis prevention measures are implemented, typically involving the administration of intravenous urokinase and prostaglandin E1 over the course of one week. Antibiotic therapy is initiated to prevent infection, with the patient receiving intravenous penicillin (1000000 units) and ampicillin (0.5g) every 4 hours for the following week to 10 days.

Immobilization is strictly advised for 6 to 8 weeks post-surgery, followed by a gradual introduction of physiotherapy to facilitate rehabilitation. Smoking is strictly prohibited during this critical recovery period to optimize healing and minimize complications. While anticoagulant therapy is generally contraindicated in cases of major amputation trauma, some practitioners may opt for prophylactic measures such as aspirin, low-molecular-weight dextran, and heparin. If aspirin is prescribed, a dose of 325mg per day is typically recommended for its beneficial antiplatelet effects, continuing for a period of 3 weeks post-surgery. (5, 11, 15)

Chen criteria

The purpose of these criteria is to aid in the assessment of the function and mobility of the patient's replanted extremity post-surgery, as well as to monitor their recovery progress over time.

Table 2: Chen's criteria for replanted extremity function evaluation

GRADE	FUNCTION
I	With a significant help from the replanted portion, the patient is able to return to work. Range of motion is more than 60% of the prior standard. Excellent degree of sensitivity recovery, without overly sensitive sensations to cold. On a scale of 1 to 5, muscle power is rated at a 4. Grade 3–5 muscular strength.
II	Able to start from where they left off, but not their original workload. Motion range surpasses 40% of ordinary. Recovery of median and ulna sensitivity close to normal, without being overly sensitive to cold. Grade 3–4 muscular strength.
III	Present independence in every day life. Motion range surpasses 30% of normal. Sensitivity recovery is not great, but useful. Grade 3 muscular strength.
IV	Tissue survival takes place, but no recoverable useful function does.

3.4.2 Digital replantation

Digital amputations, particularly involving fingertips and partial digits, are prevalent among both adults and children, often resulting from accidents while using power tools at home. Men, especially those engaged in mechanical or physical work, exhibit the highest incidence of such injuries. (5, 11, 17, 18, 20)

Indication

Indications for replant surgery encompass various factors, including the nature of the lost tissue and patient-specific considerations such as age, sex, occupation, and personal preferences. While multiple digital injuries and single thumb amputations are primary indications, patient desires sometimes diverge from surgical recommendations, underscoring the importance of patient autonomy in decision-making. While complete amputation of a single finger may not always necessitate surgery, patient preferences may override medical considerations, particularly when aesthetic concerns are paramount. Conversely, in pediatric cases, any lost tissue typically warrants replantation surgery.

In prioritizing tissue salvage, the thumb emerges as the most crucial digit, given its pivotal role in hand function. Additionally, the trio of fingers comprising the index, thumb, and middle finger, collectively known for their sensitivity and contribution to pinch grip, are prioritized. In instances where the index finger is lost, the middle finger often assumes its functional role.

The type of injury significantly influences the surgical outcome, with guillotine amputations presenting more favorable prospects compared to avulsion injuries. In cases where the skin sustains irreversible damage, amputation may be unavoidable. However, amputations distal to the interphalangeal joint are rarely replanted due to the limited functional benefit associated with their small size. (5, 11, 20)

Preoperative management

In the context of replantation surgery, a comprehensive assessment of the patient's trauma status is imperative to exclude any accompanying serious injuries. Proper handling of the amputated part is crucial, typically involving cooling to preserve tissue viability. However, due to the risk of freezing on direct contact with ice, alternative methods such as double-bagging with water or towel wrapping are employed to mitigate this risk. Despite the urgency, the warm ischemic time for fingers can extend up to 10 hours, owing to their minimal muscle content, rendering them less susceptible to damage over prolonged periods.

Before initiating surgery, medical personnel often reference Tamai's zones of amputations for digits and hands to orient themselves regarding anatomical structures. These zones delineate different levels of amputation: Zone I (distal to lunula), Zone II (proximal to lunula, distal to DIP joint), Zone III (proximal to DIP joint, distal to insertion of FDS tendon), and Zone IV (proximal to FDS tendon insertion, distal to MP joint). (Figure 3) (5, 11, 20)

Operation – sequence of repair

During the operation, two microscopes and teams are utilized to assess both the stump and the amputated digit concurrently. The patient typically receives long-acting brachial plexus anesthesia and intravenous sedation. The amputated part is briefly soaked in aqueous Hibitane (chlorhexidine) and then placed on a cryogen pad until arterial repair is completed. Surgical steps include meticulous debridement of destroyed tissue, bone shortening (usually by 0.5 to 1 cm) to allow for soft tissue recovery under normal tension, fixation of bones using

interosseous wiring or titanium screws and plates, repair of extensor tendons, vessel anastomosis (often the most challenging aspect due to the small size and susceptibility to spasm), and closure of flexor tendons and skin.

Surgeons rely on their assessment of the amputation site within Tamai's zones to gauge the complexity of the procedure. Zone I, in particular, presents unique challenges, with the artery centrally located in the pulp of the finger, necessitating precise microsurgical techniques. In some cases, the anastomosis of veins or nerves may be deemed nearly impossible, leaving the outcome to the chance of spontaneous recovery along the artery. (5, 11, 17, 18, 20)

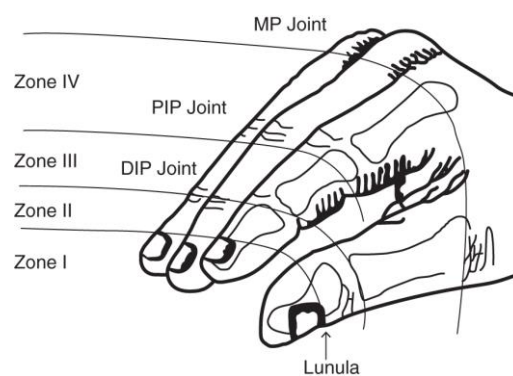


Figure 3: Tamai classification of zones in digital amputation

Postoperative management

Following surgery, a Sofra-tulle gauze is applied to the replanted digit, with circumferential dressings avoided to prevent constriction and allow for swelling. A plaster cast is then applied from the mid-forearm to the fingertips, leaving the dorsum of the digit exposed for easy monitoring. The arm is elevated above shoulder level for a minimum of 10 days, with additional fixation devices sometimes required for amputations in zones III and IV.

Medical staff vigilantly monitors the finger's temperature, color, and capillary refill time to assess circulation, occasionally employing leech therapy to enhance blood flow, particularly to the fingertips. While anticoagulants are typically avoided during surgery, a prophylactic dose of aspirin (1g) may be administered. In some cases, institutions administer intravenous heparin (5000 units) following arterial anastomoses and tourniquet deflation. Antibiotics are also routinely prescribed for prophylactic protection against infections and sepsis, as is standard practice for any open injury.

After four weeks of full immobilization, gradual introduction of physiotherapeutic movements commences to facilitate rehabilitation. (5, 11, 20)

3.4.3 Miscellaneous tissue replantation

Scalp

Scalp avulsion injuries, though rare, primarily affect women with long hair and typically occur when hair becomes entangled in machinery or fans. Remarkably, these injuries often yield excellent outcomes due to the scalp's remarkable capacity for revascularization. In most cases, even a single vessel is sufficient for the survival of the replanted scalp tissue. Surgeons have reported superior results when anastomosing the superficial temporal vessels, while in cases where this is not feasible, successful outcomes have been achieved using occipital vessels alone. Like any amputated tissue, the avulsed scalp is cooled and preferably shaved if hair is present. In instances where scalp replantation is deemed impossible, a split-thickness skin graft may be utilized as an alternative.

Given the highly vascularized nature of the scalp, the use of anticoagulants during this period is not advisable due to the potential for extensive blood loss and hematoma formation. Following surgery, the head is maintained in a Fowler position under a bulky dressing to safeguard against pressure necrosis and promote optimal healing. (5, 11)

Ear

The delicate configuration of the ear presents significant challenges for surgical intervention. The extent of tissue loss dictates the course of treatment, with small segment losses often requiring aesthetic correction through grafts with buried cartilage frameworks. Partial tissue loss involving the concha poses challenges due to the small vessels involved, typically requiring skin removal from the amputated part and subsequent coverage with local skin grafts such as temporal facial or occipital fascial flaps.

Total amputations involving the tragus and concha offer better prognoses due to easily identifiable vessels. In cases where the scalp is also involved, the protocol for scalp reattachment is followed. (5, 11)

Penis

Penile amputation, often stemming from psychological disorders and self-mutilation, requires careful management to preserve the remaining tissue for potential survival. It's crucial to

retain any small intact skin portions for later penile viability. The amputated penis should be cooled until vascular anastomoses can be performed.

The surgeon starts the procedure by patching the urethra, placing a catheter inside, and then suturing the corpus spongiosum with absorbable threads. The deep penile arteries on both sides are then anastomosed, and the tunica albuginea is repaired with interrupted stitches. The surgeon also treats Buck's fascia, the superficial dorsal vein, the deep dorsal vein, and the dorsal arteries and nerves. The process is finished with skin closure.

Following surgery, the penis is kept upright with a thick dressing and a spongy case for protection. A urethral catheter remains in place for 2 to 3 weeks. Patients receive urokinase and prostaglandin E1 for a week, with the option of using medical leeches if results are uncertain. (5, 11)

Toe

This uncommon form of amputation, typically partial, follows similar principles to digital replantation surgery. The procedure involves bone shortening and ensuring adequate skeletal immobilization. Subsequent steps include the repair of tendons, plantar nerves, dorsal veins, and dorsal and plantar arteries. However, if the injury is crushed and the vascular tissue sustains severe damage, surgical intervention is contraindicated. (5)

Other organs

In discussions regarding facial amputations, commonly referenced parts include the lip and cheek. The facial region boasts robust vascularity, typically resulting in successful tissue survival post-replantation. However, it's important to note that despite successful survival, replanted facial tissue often does not regain its original appearance. This is particularly noticeable in areas such as the lip, nasal tip, or angle of the mouth. (5)

3.5. FREE TISSUE TRANSFER (DONOR TISSUE)

Reconstructive ladder and skin flaps

Plastic and reconstructive surgeons utilize a concept known as the reconstructive ladder to guide the progression of increasingly complex procedures for wound management. With advancements in technology and medical knowledge, surgeons now often refer to using an "elevator" rather than climbing the ladder, reflecting the incorporation of new techniques and

tools. However, each surgeon develops their own indication for treatment choice regarding their training and unit organization.

In contemporary practice, additional aids have been integrated to address secondary scarring, such as fillers, implants for breast or facial reconstruction, fat transfer, composite tissue allotransplantation (especially in hand surgery), tissue expanders and tissue engineering. These innovations represent supplementary methods that, while not yet fully incorporated into the traditional reconstructive ladder, enhance the array of options available to surgeons. At the top of the reconstructive ladder are flaps, which remain among the most challenging procedures for medical professionals even today. (6)

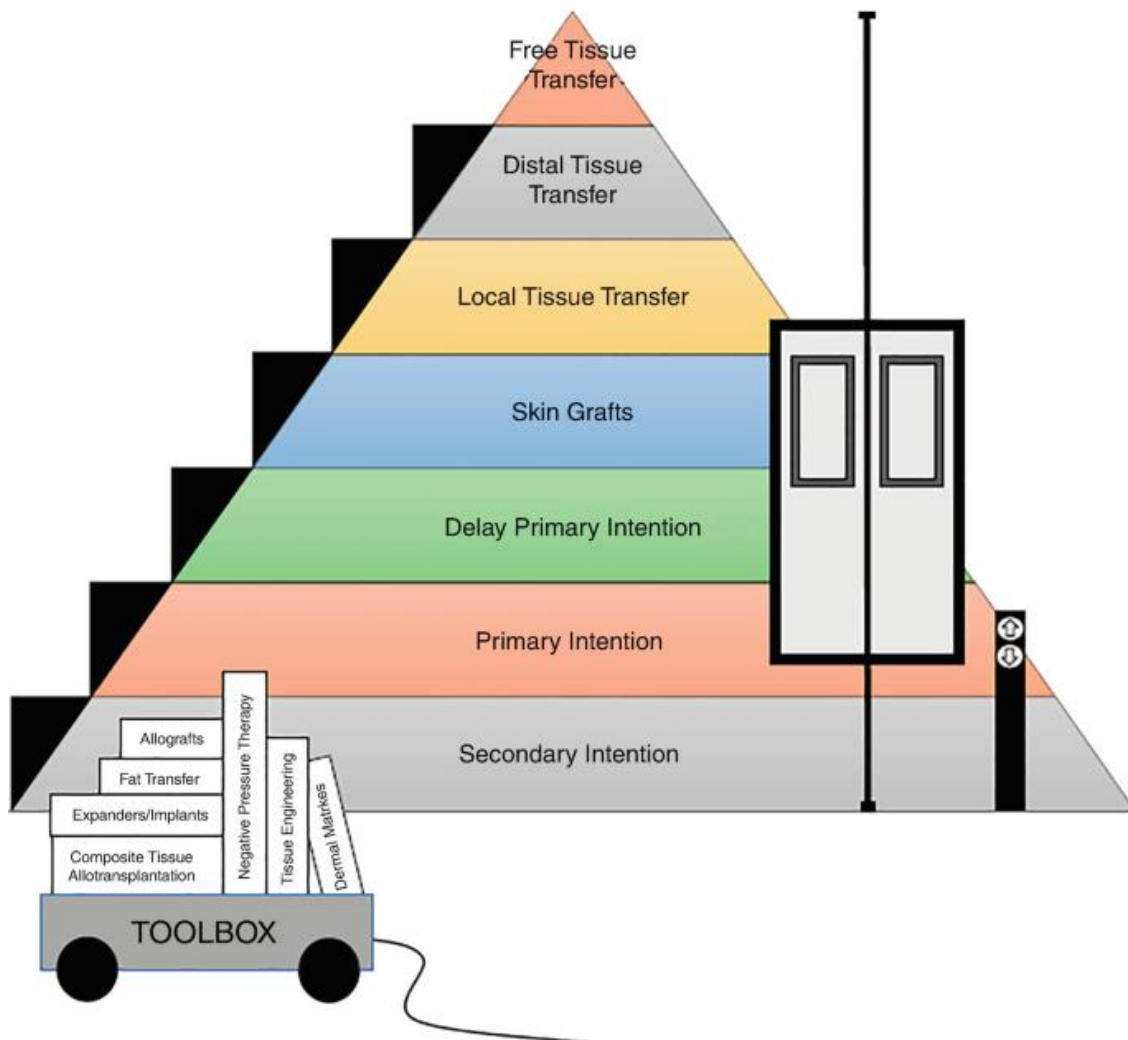


Figure 3: reconstructive ladder

Microvascular free flaps, representing the most complex area of reconstructive microsurgery, involve transferring a composite of skin and subcutaneous tissue to a distant site using microvascular techniques.(5) The complexity of this procedure arises primarily from the challenge of ensuring adequate vascularization. Consequently, free flaps are categorized into three additional groups based on their vascular supply:

1. Axial Flap: These flaps have anatomically recognized arteries and veins along the axis of the flap. Examples include the radial forearm flap, lateral arm flap, dorsalis pedis flap, and medial plantar flap.
2. Axial Plexus Flap: These flaps feature a main trunk or a branch of an anatomically recognized artery and vein in the proximal region, with the distal part being vascularized by a fascial vascular plexus. Examples include the deltopectoral flap, scapular flap, and groin flap.
3. Random Flap: These flaps are supplied by a randomly oriented vascular network, which limits their chances of survival. This group includes local flaps, rotation flaps, transposition flaps, advancement flaps, and subcutaneous pedicled flaps such as V-Y advancement flaps and transposition flaps.

Furthermore, perforating blood vessels originating from intramuscular, subcutaneous, intertendinous, or osteomuscular regions supply perforator flaps. These flaps might be classified as axial plexus flaps or random flaps. The flap is included in the axial plexus flap group if its design follows the axis of the axial fascial plexus. If the appropriate plexus connected to the perforating vessels is absent, it falls under the random flap category. Common sources for perforator flaps include the buttock, abdomen, forearm, thigh, and lower leg. (11)

There are a tremendous variety of flaps available for reconstructive surgery, covering every part of the body from head to toe. This chapter will briefly review the most commonly used flaps, highlighting their applications and benefits in different anatomical regions.

Indications for Free Flap Operation

Free flap surgery is indicated in situations requiring aesthetic coverage of wounds or defects, restoring shape and restoring function. Flaps are considered when skin grafts or local flaps are not viable solutions due to their simpler procedures, easier recovery, and lower risk for the patient. Despite this, the advanced techniques in free flap surgery have led many institutions

to prefer flap transfer because of its superior aesthetic results and the increasing expertise and confidence of surgeons in performing these procedures. (1, 5, 6)

Preoperative Care

Before the operation, a detailed inspection of the injury or defect is conducted. If an injury involves an amputated part that cannot be reattached, flaps from the amputated part may be used to cover the stump. Otherwise, a wide range of flaps from various body parts, from head to toe, can be selected. Surgeons typically prepare the wound by removing all necrotic or infected tissue through debridement, aiming for delayed primary or secondary coverage. In certain situations, a skin transplant may cover the wound temporarily until the flap procedure can be completed. (5)

Surgery technique

For a successful free flap surgery, two surgical teams are needed: one for the recipient site and one for the donor site. The team at the recipient site prepares the vessels for anastomosis by removing and excluding all damaged vessels, occasionally needing to add vascular grafts. Irradiated vessels are avoided due to their compromised viability. Locating suitable vessels can be challenging, necessitating a thorough understanding of anatomy and pathology. Surgeons may use Doppler probes or venography to assist in vessel identification. The recipient site must precisely match the size and convex shape of the donor site, following a pre-planned route without deviation.

Meanwhile, the donor team dissects the flap but does not disconnect the vessels until the recipient site is completely ready. The donor site is chosen in advance, ensuring it is of adequate size, creates minimal or no secondary defect, and has aesthetic properties similar to the tissue being replaced. Preference is given to end-to-end anastomosis, although this is not always possible, especially in lower limb reconstruction.

Intraoperatively, the success of the anastomosis can be monitored using microvascular flowmetry to assess flap perfusion. Fluorescence angiometry, an invasive procedure involving the injection of indocyanine green and detection with a digital camera, can also be used. However, noninvasive methods are generally preferred for intraoperative monitoring to reduce additional risks to the patient.

By following these detailed and carefully planned steps, the likelihood of a successful free flap operation is significantly increased, providing optimal outcomes for the patient's reconstructive needs. (5, 6)

Postoperative care

The operated area of the newly attached flap needs to be left exposed for hourly check-ups during the first 24 hours post-surgery, as this is the period when vascular complications are most likely to occur. The area can be mildly elevated, if possible, to help reduce edema, although this is often difficult to avoid due to the ischemic period and lymphatic obstruction. Medical staff must conduct hourly examinations, checking for color, warmth, and capillary return. Surgeons may use laser Doppler for better visualization of the flap's perfusion. Any changes, such as border bleeding, paleness, sluggish capillary return, a tense feeling, or dark color, need to be reported immediately. Immediate action is crucial in cases of venous obstruction or arterial insufficiency, often necessitating a second operation. (5, 6)

Possible complications

Most complications of a flap in the local region itself are related to the vascular issues previously mentioned. If the problems are solvable without operation, such as when a tight dressing needs to be changed immediately to prevent possible vascular compromise, swift action is necessary. However, if complications arise from the failure of the anastomosis, such as arterial thrombosis, the patient must return to the operating theater.

Infections are very rare, especially with the use of prophylactic antibiotics and careful wound management. General complications are associated with anesthesia and prolonged surgery. These include positional problems like neuropraxia, deep venous thrombosis, and postoperative respiratory issues. Pulmonary embolism is also a significant risk factor for any longer surgery. (5)

3.5.1. Head and neck

Scalp flap

The scalp provides free segments for transfer using superficial temporal or occipital vessels. Initially used for reconstructing burn areas or small avulsion injuries, these flaps are now also used for male pattern baldness treatment. Scalp flaps can extend from the temporal region,

passing anteriorly and posteriorly across the parieto-occipital region. Segments up to 3 to 4 cm can be transferred on the superficial temporal system.

Occipital flap

Indications for this flap are similar to those for scalp flaps, but it is based on occipital vessels and is chosen when there is insufficient hair on the superficial temporal system. The width of the flap cannot exceed 3 cm.

Temporal artery facial scalp flap

Based on superficial temporal vessels, the fascia covering the temporalis muscle can be employed as a free flap. It is suitable for ipsilateral ear or facial reconstruction after careful exposure from the scalp.

Fascial scalp flap with periosteum

This flap, originating from the temporalis fascia and periosteum, it's also be based on the superficial temporal vessel system and does not include the skin. It is a thin flap used to cover exposed bony defects, especially in fractures. However, skin grafting is required after its transfer.

Post-auricular flap

A thin cutaneous flap from behind the ear and adjacent mastoid skin, vascularized by the post-auricular artery and vein, can be obtained in a size of 5 by 7 cm. It is ideal for facial defects due to its similarity in texture and color. (5, 11, 27)

Supraclavicular flap

This thin cutaneous flap, approximately 20 cm long and 6 cm wide, extends from the suprascapular fossa transversely beyond the acromioclavicular joint. The cutaneous branch of the superficial division of the transverse cervical artery supplies it. Due to its similar texture and color to facial skin, it is suitable for facial reconstruction. (5, 11)

3.5.2. Trunk

Groin flap

One of the earliest used grafts comes from this region of the body. It is a very large cutaneous flap located over the iliac crest, which can include the iliac crest if needed, and is supplied by the superficial circumflex iliac artery and vein. This flap has a maximum size of 30 cm by 15 cm. It is hairless and, due to its reliable anatomy, is also used in emergency settings for defects of the hand, finger, wrist, forearm, or elbow. (5, 11)

Lateral thoracic flaps

In this group of flaps, we include the latissimus dorsi myocutaneous flap and the lateral thoracic cutaneous flap. The latissimus dorsi flap can extend from the axilla to the iliac crest but remains very thin within a range of 10 cm. It is dissected rapidly, easily, and safely due to the stable anatomy of the thoracodorsal and suprascapular vessels. Combined with muscle, it can camouflage some defects due to its bulkiness, particularly in lower leg reconstruction. However, Dr. Marko Godina discontinued its use for the lower leg in 1981 because its protective capacity was eventually found to be inadequate. (5, 19)

The lateral thoracic cutaneous flap is innervated by cutaneous branches of the lateral costal nerves and is based on the lateral thoracic artery. It is thinner in males and bulkier in females, making it difficult to choose, especially in males, due to the possibility that vessels cannot adequately support the flap. (11)

Back region

From the back side, scapular and parascapular flaps can be obtained. The more commonly used scapular flap is a purely cutaneous type, which lies over the infraspinous region of the scapula. It is based on the circumflex scapular artery and can have a length of up to 12 cm, extending from the deltoid region laterally to the midline medially. Dissection is rapid and safe due to the large diameter of the vessel.

The parascapular flap is a vertically oriented cutaneous flap based on the descending branch of the circumflex artery and can be obtained in sizes up to 30 by 15 cm. (5, 11)

Abdominal region

In this region, the rectus abdominis flap is most commonly used. It is a myofasciocutaneous flap comprising the skin and its underlying anterior rectus sheet with the rectus abdominis

muscle, based on the superior-inferior epigastric arterial anastomosis. This flap is versatile and can be used in defects of chest or abdominal wall and reconstruction of the breast without the need for implants. Additionally, it can be rotated inferiorly for reconstruction of groin, trochanteric, perineal, and upper thigh defects.

The rectus abdominis muscle alone can additionally be used as a muscle flap based on the inferior epigastric vessels for lower limb defects. (5, 11)

Anterior thoracic

In this region, we include deltopectoral flaps vascularized by the perforating second anterior intercostal vessel arising from the internal mammary artery. The flap is thin and can be used in facial reconstruction, although it is not considered ideal for this purpose. (5, 11)

3.5.3. Upper limb

Deltoid flap

The cutaneous flap overlying the upper posterolateral component of the upper arm is centered over the junction between the posterior border of the deltoid above and the triceps below. It is supplied by the posterior circumflex humeral artery and innervated by the cutaneous branch of the circumflex nerve. This flap is relatively thin in males, with large diameter vessels, allowing for the safe transfer of up to 8x10 cm. However, it leaves a significant scar, which often makes it less desirable, particularly among females. (5, 11)

Medial upper arm flap

This flap represents a thin cutaneous flap from the middle to the distal two-quarters of the medial component of the upper arm. It is based on the branches of the brachial artery, most commonly the superior ulnar collateral artery, and is innervated by the medial cutaneous nerve. It is indicated for a wide range of reconstruction situations, including the hand, head, neck (intraorally), distal lower leg, and ankle. (5, 11)

Lateral upper arm flap

This flap provides a thin and narrow septocutaneous flap from the lower antero-lateral aspect of the upper arm extending to the forearm, supplied by the terminal branches of the profunda brachii artery. The flap is usually thin in men and fatty in women, making it suitable for reconstructing defects in the heel, ankle, foot, hand, neck, and head. (5, 11)

Cubital flap

A very rarely indicated flap, due to its anatomical inconsistency, is this thin cutaneous flap based on the inferior ulnar collateral artery, located over the lower third of the medial aspect of the arm. (5, 11)

Forearm radial artery flap

This long, narrow fasciocutaneous flap is situated above the radial artery on the volar surface of the forearm. It is easily dissected with large, reliable vessels. This flap can be relocated without anastomoses to the elbow region or for dorsal or volar hand defects. Additionally, it can be used for intraoral reconstruction and, with small segments of radius bone, in mandibular reconstruction. (5, 11)

Ulnar artery flap

Because of its well-padded muscle bed and hidden location along the ulnar artery in the proximal and central third of the forearm, the thin fasciocutaneous flap is preferred. It is therefore more attractive to be used. Depending on the needs, the ulnar bone, flexor carpi ulnaris muscle, or tendon can be included in the flap. (5, 11)

3.5.4. Lower limb

Buttock region

The superior and inferior gluteal flaps are large and bulky myocutaneous flaps. The superior gluteal flap, supplied by the superior gluteal artery, extends obliquely from the posterior superior iliac spine towards the greater trochanter and is suitable for breast reconstruction. However, its limited reach often makes the inferior gluteal flap more preferable. The inferior gluteal flap, based on branches of the inferior gluteal artery, can be elevated at the level of the buttock crease. Surgeons have to exercise caution when dissecting to prevent injury to the sciatic nerve. (5, 11, 19)

Medial thigh region

The medial thigh region provides several flap options: gracilis myocutaneous and free muscle flap, lower medial thigh flap, and anteromedial thigh flap. Among these, the gracilis myocutaneous flap is most commonly used. It provides a long, narrow strip that is frequently utilised for local transfers and is situated over the proximal two-thirds of the gracilis muscle,

based on the profunda femoris artery. The gracilis muscle is easily and safely transferable with a large, long nerve, making it useful for facial paralysis reanimation and extremity muscle function. The lower medial thigh flap includes skin over the central and lower thirds of the thigh, just above the femoral condyle, and is supplied by a cutaneous branch from the femoral artery. A cutaneous branch from the femoral artery supplies the anteromedial thigh flap, which is very large and spans the middle 2/4 of the anteromedial thigh. However, its thickness and the potential for significant secondary defects make it less favorable for use.

Lateral thigh region

The lateral thigh presents four flap possibilities: the tensor fascia lata flap, anterolateral thigh flap, posterolateral thigh flap, and superior posterolateral thigh flap.

The tensor fascia lata flap is a myocutaneous flap supplied by the lateral circumflex femoral artery, encompassing the tensor fascia lata muscle and fascia lata tendon across the entire lateral thigh. While large and thick, this flap is easy and safe to dissect, but it often yields poor aesthetic secondary results.

The anterolateral thigh flap is a massive fascioseptal flap extending from the great trochanter to the popliteal fossa and spanning the anteromedial to posterolateral thigh. Its foundation is the cutaneous branch of the lateral circumflex artery's descending branch. The posterolateral fascioseptal thigh flap covers the entire posterolateral aspect of the thigh, from the gluteal fold to the popliteal fossa. It is based on the cutaneous branch of the third perforator of the profunda femoris artery.

Finally, the superior posterolateral thigh flap is a fasciocutaneous flap based on the first perforating branch of the profunda femoris artery. It is primarily used for defects in the ischial or trochanteric areas.

Knee region

From the medial aspect of the knee joint, the saphenous flap can be harvested. This cutaneous flap overlays the medial femoral condyle and the middle tibial plateau, and it is based on the saphenous branch of the descending genicular artery. The flap tends to be thinner in male populations and is typically utilized for addressing issues such as pressure sores or denervated areas. Importantly, it can be transferred with its nerves intact, potentially allowing for innervation by the saphenous nerve on the lower portion of the flap and the medial femoral cutaneous nerve on the upper part.

Lower leg

The anterior tibial artery flap is a thin but sizable flap positioned over the anterior tibial artery, covering the proximal 1/3 of the extensor and peroneal compartments. Due to its length, it is often employed for reconstructive procedures involving the lower leg, ankle, foot, or sole. Additionally, it can serve as an osteocutaneous flap when including a segment of the tibia. The peroneal flap is an extremely thin flap relying on cutaneous perforators from the peroneal artery, situated along the lateral aspect of the mid-lower third of the lower leg. Because of its thin nature, it finds utility in reconstruction procedures involving the hand, foot, head, and neck. When combined with a portion of the fibula bone, it can also be utilized for heel reconstruction. Lastly, the sural flap is a thin fascioseptal flap located along the midline of the upper portion of the calf, reaching up to 6 cm in width. The popliteal artery's sural branches, which have a significant diameter, provide its blood supply. (5, 11, 16, 19)

3.5.5. Foot

Dorsal foot flap

The dorsal foot flap, supplied by the dorsalis pedis artery and saphenous vein, is often utilized for hand, posterior heel, and intraoral reconstructions due to its size, hairlessness, thinness, and large vessels. It can also be used in conjunction with the phalanges and second metatarsal for anterior mandibular reconstruction, as well as the dorsal hand reconstruction if the extensor tendons are included. (5, 11, 21, 22)

Extensor tendons-vascularized free transfer

The extensor hallucis brevis or extensor hallucis longus tendon can serve as a vascularized free flap when conventional grafting is likely to yield unsatisfactory outcomes. Typically employed in zone 2 (Figure 3) flexor tendon injuries in the hand, this approach offers an alternative method for tendon reconstruction, potentially improving functional outcomes.

Mid-sole plantar flap

The fasciocutaneous flap sourced from the area between the heel and metatarsal heads, supported by the medial or lateral plantar neurovascular bundles, offers a unique mechanical function conducive to weight-bearing. Consequently, it finds utility in reconstructive procedures involving the sole of the foot, heel, and various regions of the middle and forefoot plantar areas. (5, 11, 21, 22)

3.5.6. Toe transfer

First web space hemipulps and nail

The flap sourced from the hemipulp of the big and second toe presents a unique composition comprising skin, pulp, and even a nail. This specialized structure makes it particularly well suited for digital reconstruction purposes. The dorsal artery system provides its circulatory supply, but because these arteries are so tiny, retrieval can be difficult.

Nail

The most common and successful nail transfer involves relocating the nail from the big toe to the thumb on the hand. During the dissection and transfer process, surgeons must ensure the inclusion of the dorsal portion of the hemipulp to preserve the nerve and artery supply to the nail bed. Additionally, at least 1cm of dorsal skin proximal to the nail should be included to facilitate venous drainage.

Joint transfer

To reconstruct proximal interphalangeal joints on fingers, metacarpophalangeal joints, or even the mandibular joint, surgeons can utilize the proximal interphalangeal or metatarsophalangeal joints of the toes. These joints are based on the dorsal arterial system. Typically, the second toe is sacrificed for such procedures, as it is the optimal choice for wrist reconstruction.

Hallux transfer

In wrist reconstruction and injuries to the thumb proximal to the metacarpophalangeal joint, a comprehensive array of structures is transferred. This includes the skin and bones of the big toe, along with the tendons of the extensor hallucis longus, extensor hallucis brevis, and flexor hallucis longus. Additionally, tendon stumps of the abductor and first dorsal interossei, the dorsal artery and long saphenous vein, and both plantar digital nerves are transferred.

Second toe transfer

The second toe is highly regarded for subtotal thumb or distal finger reconstructions. It is removed using V-shaped incisions on the dorsal and plantar sides, proximal to the toe. One division from the first dorsal metatarsal artery is dissected, while the other is preserved for the big toe.

Second and third toe - “en blanc”

In cases requiring more tissue for significant finger defects, surgeons may opt for the "en bloc", transfer of the second and third toes. This procedure involves taking both toes together, deriving their blood supply from the second plantar metatarsal artery and the first and second dorsal metatarsal arteries.

Wrap around

For complete coverage of the thumb, surgeons typically harvest skin, including the nail and pulp, from the big toe. Additionally, bone grafts from the iliac crest may be utilized and enveloped with this flap. Its blood supply is derived from the dorsalis pedis and dorsal metatarsal arterial system, while the plantar digital nerves provide innervation. (5, 11, 21, 22)

3.5.7. Abdominal cavity

Microvascular transfer of omentum

The omentum, a large double sheet of peritoneum, offers abundant blood supply, fat, and lymphatics. It originates from the great curvature of the stomach, draping over the small intestine and transverse colon. Its rich vascularization and flexibility make it valuable for tissue coverage, especially for exposed bone surfaces. In abdominal surgery, it is utilized for various purposes such as managing visceral leaks and fistulae, addressing retroperitoneal fibrosis, and in urogenital procedures. Outside the abdomen, it serves as a free flap for lymphedema decompression, breast and chest wall reconstruction, and treating cerebral ischemia. Plastic surgeons often employ it for scalp resurfacing, degloved hand reconstruction, and correcting facial asymmetry. However, its retrieval may necessitate laparoscopy, which carries risks such as peritonitis, abdominal wall rupture, adhesions, or hernia formation, particularly after major abdominal surgeries. (5, 11)

Bowel transfer

The jejunum remains a primary choice for reconstructive surgery involving the esophagus and pharynx. Surgeons typically harvest the jejunum just distal to the duodenojejunal flexure. The opened segment of the jejunum is particularly well suited for lining the oral cavity, including the tonsillar fossa or soft palate, due to its favorable characteristics for mucosal reconstruction. (5, 11)

3.5.8. Vascularized bone grafts

In contrast to other free microvascular flaps, a free bone flap, when taken from one location and reattached to another, experiences a significant portion of its cells dying due to the relative lack of vascularity in the graft bed. On the other hand, the residual bone flap matrix acts as a support system for the proliferation of neighbouring osteogenic-potential cells.

Fibula

Vascularized by peroneal vessels, up to 30cm of bone can be obtained for grafting purposes. This bone flap is stronger and longer than the iliac crest and can be employed for all limb bone defects, spanning up to 15cm in length, with or without accompanying skin cover.

Soleus and bone combined

The soleus muscle can be combined with bone, creating a flap based on the peroneal vessel supply. Typically employed to reconstruct bone and skin defects in other areas of the middle one-third of the lower leg.

Iliac crest

The iliac crest, along with its overlying skin, receives vascular supply from the superficial circumflex iliac artery, with the bony portion also being supported by the deep circumflex iliac artery. This necessitates the inclusion of both branches in the flap. Unlike the fibula, the iliac crest is better suited for bone defects under 10-12cm. It is commonly employed in major mandibular reconstruction or in cases of significant leg bone and skin defects where the fibula, along with the soleus muscle, may not provide adequate coverage for the entire defect.

Metatarsal bone

The metatarsal bone of the second toe, although small in size, is easily accessible and can be utilized for smaller mandibular or forearm bone defects, particularly in cases of radionecrosis or non-union.

Radius, ulna, humerus and scapular bones

These bones can provide a wide range of free bone grafts depending on the situation and the surgeon's needs. Half of the circumference of the radius or ulna at the level of the junction of the middle and distal thirds can be utilized as a graft, including their overlying skin, based on

their radial or ulnar arteries. Additionally, the humerus bone can be used in combination with the lateral upper arm flap, and the scapula can be used with the scapular flap.

Rib

The sixth and seventh ribs, based on their internal mammary vessels and anterior intercostal branches, are useful in mandibular deficiencies and reconstructions.

Periosteal flaps

In situations where a flap is needed in conjunction with underlying comminuted fractured bone segments or non-union cases, a vascularized periosteal flap may be considered. For instance, a large sheet of vascularized periosteum and overlying muscle can be harvested from the inner part of the entire ilium, utilizing the deep circumflex iliac vessel system. However, the clinical use of this approach remains a topic of debate. (5, 11)

3.6. MICROSURGICAL RECONSTRUCTION

By this chapter, we been through all techniques and ranges or possibility of reconstructive microsurgery and the following provides a short overview of the extensive possibilities offered by microsurgery in the realms of plastic and reconstructive surgery. Their main goal, on any part of the body, is to restore good esthetics together with best functionality possible.

3.6.1. Upper limb

Upper limb reconstruction poses a significant challenge for microsurgeons due to its superior functional outcomes compared to prosthetics. This review delves into the evolution of microsurgical techniques in upper limb reconstruction, emphasizing the critical role of timely intervention and informed decision-making in achieving optimal results.

Initially, the preference lies in replanting severed digits or limbs, prioritizing essential structures like the thumb for their pivotal function in hand dexterity. Early and comprehensive reconstruction is advocated to minimize complications and maximize functional recovery.

This approach entails meticulous attention to detail, addressing dead spaces, ensuring skeletal stability, and providing adequate soft tissue coverage for optimal tendon and muscle function.

Surgical decision-making hinges on the assessment of tissue viability and the extent of injury. Preservation or amputation of the limb depends on factors such as the potential for functional recovery and the presence of skin defects. Microsurgical advancements have expanded the possibilities for salvaging previously deemed unsalvageable limbs, although severe cases may still necessitate amputation. In such instances, microsurgery plays a crucial role in preserving stump length and utilizing spare parts for reconstruction.

The timing of reconstruction is paramount, with better outcomes associated with early intervention, ideally within 24 to 72 hours post-debridement. Various approaches to flap transfers have been proposed, ranging from immediate emergency procedures to delayed interventions beyond seven days. Early reconstruction not only facilitates faster rehabilitation but also contributes to improved overall outcomes.

Advancements in microsurgery and vascular anatomy have significantly enhanced the field, leading to reduced amputation rates and improved functional outcomes. While perforator flaps offer distinct advantages, traditional microsurgical techniques still hold relevance in certain cases. Furthermore, ongoing research, particularly in immunosuppression, holds promise for expanding treatment options, such as upper limb allotransplantation, for non-salvageable extremities. (5, 11, 17, 23, 24)

3.6.2. Lower limb

Reconstructive microsurgery has revolutionized limb-saving procedures, especially for severe lower extremity injuries. Initially, pedicled local flaps were common, but now microsurgical free tissue transfer is preferred for bigger or complex defects. Innovations like perforator and free-style flaps have further refined this approach. This article explores the pivotal role of advanced microsurgical techniques in lower limb salvage and reconstruction.

Microsurgical free tissue transfer finds indications in various conditions including segmental bone loss, muscle loss, osteomyelitis, tumor excision, burns, and chronic ulcers. It's a viable option even for elderly or medically complex patients, with children benefiting notably. Moreover, it can aid in preserving limb length for prosthesis fitting in amputation cases. Deciding between limb salvage and amputation is multifaceted, considering patient factors and socioeconomics. While severity scores offer guidance, decisions often require individualized assessment. Studies generally favor salvage attempts due to comparable

outcomes and significant impacts on patient satisfaction, notably in terms of function and well-being, as demonstrated by Godina's work.

Timing is crucial, with early soft-tissue coverage within 72 hours shown to reduce complications and hospital stays. However, timing should be adjusted to individual circumstances, balancing the patient's overall health and injury severity.

Soft-tissue coverage has evolved, with microsurgical free flaps now preferred as the first-line choice. Flap selection depends on wound characteristics, with pedicled flaps suitable for smaller defects and muscle flaps ideal for combating infection and dead space.

Fasciocutaneous flaps are gaining popularity for their functional and aesthetic advantages, with the anterolateral thigh flap highlighted for its versatility.

Bony reconstruction often necessitates vascularized bone grafts, with the fibula flap being a common choice due to its robust cortical bone. Timing of bone grafting should be tailored to individual cases, considering the need for staged reconstruction when extensive debridement or dead space management is required.

In conclusion, this article underscores the significant advancements in microsurgical techniques for lower extremity reconstruction, emphasizing early intervention, meticulous flap selection, and personalized treatment planning to optimize patient outcomes. (5, 11, 19, 25, 26)

3.6.3. Trunk

Trunk wall

Flap closure of the chest or abdominal wall is typically indicated following tumor ablation or irradiation necrosis, with breast cancer being a common cause. Larger defects are effectively covered by various flaps depending on the need for rigidity, bulk, or cosmetic outcome. The tensor fascia lata, latissimus dorsi, groin, parascapular, or combined flaps are suitable for extensive defects. The groin flap, though smaller and less safe, offers good cosmetic results. In cases of flail chest, the opposite side serratus anterior muscle flap with underlying ribs provides optimal coverage. Omentum is often utilized for volume augmentation when necessary. (5, 11)

Breast reconstruction

Breast cancer, the most prevalent cancer in women, often leads to mastectomy. Techniques like tissue expander implants and autologous tissues offer options for its reconstruction. Microsurgical tissue transfer, employing skin and fat from distant sites, commonly the abdomen (latissimus dorsi muscle) or buttocks (superior gluteal flap), and less often, thighs, yields durable, aesthetically pleasing outcomes. Advances in microsurgery have pushed success rates to 99%. Flap selection for reconstruction depends on patient factors, comorbidities, body type, cancer stage, need for radiation therapy, and contralateral breast cancer risk. Proper flap and technique selection mitigate operative risks. (5, 11, 27)

3.6.4. Head and neck

Initially, head and neck reconstruction in microsurgery relied on basic grafting techniques. As technology advanced, sophisticated microsurgical methods emerged, broadening reconstructive possibilities. These advancements integrate intricate techniques with deep anatomical understanding. Free flaps, retaining their blood supply, revolutionized microsurgery. Perforator flaps, sparing muscles and nerves, minimize donor site morbidity, offering versatile solutions for complex defects.

Comprehensive planning is vital, involving imaging studies, anatomical mapping, and strategic surgical approaches to optimize outcomes. Surgeons evaluate defects, select donor sites, and anticipate complications.

Common flap types include the radial forearm flap, valued for its reliability and versatility in soft tissue defects, and the fibula free flap, preferred for its robust bone stock in mandibular reconstruction. Other options like the iliac crest, metatarsals, and ribs are also utilized. The anterolateral thigh flap, known for its large skin paddle and minimal donor site morbidity, is another popular choice. For oral cavity and pharynx reconstruction, the jejunum flap remains ideal due to its mucosal functionality.

Restoring smile function in facial palsy presents a significant challenge. Treatment typically involves a two-step process: free functional muscle transfer after the implantation of a cross-facial nerve graft, frequently using the gracilis muscle.

Effective postoperative care involves vigilant monitoring of flap viability, pain management, and infection prevention. Long-term check-up is crucial to evaluate functional and aesthetic outcomes and address any late complications. (5, 11, 28, 29)

3.6.5. Lymphatic system

Recent advancements have greatly improved our understanding and management of both primary and secondary peripheral lymphedemas. However, non-surgical approaches primarily aim at reducing morbidity rather than addressing the root cause. Microsurgical procedures, encompassing both derivative and reconstructive surgeries, have demonstrated efficacy in restoring lymphatic drainage both short- and long-term, particularly when combined with physical rehabilitation techniques.

Diagnostic Imaging, notably lymphoscintigraphy using ^{99m}Tc -labeled antimony sulfur colloid, plays a crucial role in diagnosing lymphedema and selecting appropriate patients for derivative microsurgical procedures. This imaging method effectively distinguishes lymphatic-origin edema, providing essential etiological and pathophysiological insights. Echo Doppler is also utilized to detect associated venous disorders, often corrected concurrently with microsurgical procedures.

Surgical Techniques vary based on the nature of lymphedema. Reconstructive techniques like the lymphatic-venous-lymphatic (LVLA) plasty are preferred for lower limb lymphedema complicated by surgically uncorrectable venous disease. This approach involves using an autologous vein graft to bypass lymphatic obstructions, maintaining lymph flow through appropriately directed venous segments.

Assessment of the effectiveness of these microsurgical interventions is based on volume reduction, stability over time, decreased frequency of dermatolymphangioadenitis attacks, and reduced need for ongoing conservative treatments. Outcomes vary depending on the lymphedema stage treated.

Lymphatic microsurgery is most beneficial early on in the development of lymphedema, particularly stages IB, II, and early III, characterized by low lymph nodal uptake in lymphoscintigraphy and minimal tracer passage beyond proximal nodes. Ideal candidates exhibit excellent compliance and have access to specialized lymphological and surgical centers.

For advanced stages of lymphedema, such as stages III, IV, and V, it is essential to reduce severity through non-operative methods before considering microsurgery. Post-operative care plays a critical role in maintaining and enhancing surgical outcomes long-term.

Relative contraindications to lymphatic microsurgery include lymphatic-lymph nodal aplasia, diffuse metastatic disease, and advanced stage V lymphedema unresponsive to conservative

therapy. Conventional debulking procedures are less preferred and should only be used in cases of late-stage lymphedema following substantial edema reduction with other therapies. In conclusion, lymphatic microsurgery, when integrated with diagnostic imaging and appropriate post-operative care, provides a viable solution for managing various stages of lymphedema. Combined with ongoing physical therapy, these surgical techniques significantly improve patient outcomes and quality of life. (4, 5, 11, 32, 33)

3.6.6. Urogenital system

Vas deferens and epididymis

Since 1971, an innovative microsurgical approach has facilitated the reversal of vasectomies in 2,110 men called vasovasostomy. Employing a meticulous two-layered technique, surgeons endeavored to anastomose both sides whenever feasible, supplementing with reinforcing sutures to mitigate strain on the connection. Key practices included assessing fluid from the testicular end, confirming patency of the prostatic end, and emphasizing adequate scrotal support during the critical initial recovery phase.

Other surgery on this level represents vasoepididymostomy, a microsurgical intervention for epididymal obstruction, represents the most intricate and demanding procedure for treating male infertility. Surgeons require exceptional microsurgical proficiency and significant experience to conduct this delicate anastomotic connection between the vas deferens and the epididymis. (5, 11, 30, 31)

Fallopian tube

Tubal re-canalization, a specialized procedure for addressing tubal factor infertility, involves laparoscopy for real-time imaging and assessment of the fallopian tubes. Microsurgical techniques delicately handle tube structures to minimize tissue trauma. Evaluation guides precise interventions to remove obstructions or repair damage, restoring unobstructed patency for natural fertilization. Intravascular stenting may be employed post-surgery to maintain tubal patency and enhance long-term fertility outcomes, contingent upon individual factors and patient-provider discussion. (5, 11, 32)

Testicular transfer

Orchidopexy is a surgical procedure for impalpable undescending testis. The procedure for high inguinal or intra-abdominal testis is division of testicular vessels and staged orchidopexy has been recommended. However the testis transplantation is being explored. (5, 30, 31)

3.7. RECONSTRUCTIVE MICROSURGERY TODAY

Supermicrosurgery

Treatment for lymphedema and soft tissue restoration have advanced significantly thanks to a procedure that focuses on dissecting and anastomosing tiny vessels, typically measuring 0.3 to 0.8 mm. Its advantages include the capacity to dissect short pedicles on a suprafascial plane, which lowers donor-site morbidity, and the ability to manipulate small arteries that were previously unreachable. Over the past 20 years, supermicrosurgery—which was first created for fingertip salvage—has changed and expanded its uses to encompass lymphovenous anastomoses, vascularized lymph node transfers, and perforator-to-perforator anastomoses. With continued high-quality outcome research and training standardisation, supermicrosurgery has the potential to become a cornerstone of the practice of every microsurgeon. (5, 30, 31)

Microsurgical robot

Innovative techniques can surmount the constraints of human anatomy. Microsurgery demands optimal vision and precise instrument maneuvering, areas where the human eye and hand are inherently limited. While conventional microsurgery relies on operation microscopes for enhanced visualization, emerging high-definition 3D cameras offer a potential alternative, augmenting surgeon ergonomics. However, the human hand remains a limiting factor. To address this, a specialized microsurgical robot has been developed to heighten precision and stability. Presenting a pioneering case in reconstructive microsurgery, this integration of technologies pairs a dedicated microsurgical robot with a 4K 3D exoscope, marking a significant advancement in the field. (35, 36)

Microsurgical imaging techniques

The evolution of microsurgery faces a common hurdle: the variability in patient anatomy. While traditional imaging techniques like CT scans and MRIs have limitations, recent advances in portable ultrasound technology have revolutionized preoperative planning. High

frequency and ultra-high-frequency ultrasound offer detailed insights, reducing the need for exploratory dissections and enhancing safety and efficacy in microsurgical procedures.

Ultrasound proficiency allows surgeons to select the most suitable flaps based on microanatomy, facilitating innovations like thin and super-thin flaps. Moreover, emerging technologies such as intraoperative microscope-integrated laser tomography and photoacoustic imaging promise further improvements in outcomes and safety.

Plastic surgeons and microsurgeons must remain abreast of these advancements, as they have the potential to transform microsurgical practice. Integration with augmented reality and artificial intelligence software may open new frontiers, advancing safety, efficacy, and cost-effectiveness in microsurgery. (37, 38)

4. DISCUSSION

Reconstructive microsurgery has demonstrated significant advancements and applications, fundamentally altering the landscape of surgical reconstruction. The insights gained from this study underline the transformative potential and the inherent challenges of this specialized field.

The precision and efficacy of microsurgical techniques, such as microvascular and microneural procedures, have enabled remarkable successes in tissue reattachment and repair. These techniques have become crucial in addressing complex cases involving traumatic injuries, congenital anomalies, and oncological resections. The ability to perform intricate surgeries on small anatomical structures has not only improved functional outcomes but has also enhanced the aesthetic results, which are vital for patient rehabilitation and overall quality of life.

A significant aspect of this review paper has been the exploration of free tissue transfers. These procedures, which involve the transplantation of tissue from one part of the body to another, have proven indispensable in reconstructing defects caused by trauma or disease. The revascularization of transplanted tissues through meticulous anastomosis has ensured high success rates, making it possible to repair extensive and previously irreparable defects.

However, the field of reconstructive microsurgery is not without its challenges. The high level of expertise required for these procedures necessitates extensive training and experience, posing a barrier to the widespread adoption of these techniques. The cost of specialized equipment and the need for a multidisciplinary team approach further complicate accessibility, especially in resource-limited settings. Additionally, the meticulous nature of these surgeries often results in prolonged operating times and necessitates comprehensive postoperative care, which can strain healthcare resources.

Recent technological advancements have continued to expand the capabilities of reconstructive microsurgery. The development of super-microsurgery, which involves working with extremely small blood vessels and lymphatic channels, has opened new therapeutic avenues, particularly for conditions like lymphedema. These advancements require ongoing innovation in surgical instruments and techniques, underscoring the dynamic and evolving nature of the field.

Postoperative care and rehabilitation are critical components of successful microsurgical outcomes. Effective postoperative protocols and multidisciplinary rehabilitation strategies are essential for ensuring optimal recovery and functional restoration. This comprehensive approach to patient care is crucial in addressing both the physical and psychological aspects of recovery, thereby enhancing the overall quality of life for patients.

Looking ahead, the future of reconstructive microsurgery appears promising. Continued research and innovation are expected to address current limitations and further refine surgical techniques. Potential advancements include improved imaging methods for better surgical planning, the development of advanced biomaterials for tissue engineering, and the integration of robotic technology to enhance surgical precision and reduce operative times. Addressing these challenges through ongoing research and technological development will be pivotal in advancing the field and expanding its impact on patient care.

5. CONCLUSION

Reconstructive microsurgery has emerged as a pivotal field in modern surgery, transforming the way complex reconstructive challenges are approached. Through the precise manipulation of tiny anatomical structures, microsurgical techniques have significantly improved outcomes

for patients with severe trauma, congenital anomalies, and oncological defects. Free tissue transfers, in particular, have revolutionized reconstructive surgery by allowing for the successful transplantation and revascularization of tissues, leading to enhanced functional and aesthetic results.

Despite the remarkable advancements, the field faces challenges such as the need for extensive training, high costs, and the complexity of postoperative care. However, continuous research and innovation promise to address these barriers, with emerging technologies like super-microsurgery and advanced imaging techniques paving the way for even greater precision and efficacy.

Looking forward, the integration of new technologies and materials, along with a multidisciplinary approach to patient care, will be crucial in further advancing reconstructive microsurgery. The ongoing evolution of this field holds the potential to significantly enhance patient outcomes and quality of life, ensuring that reconstructive microsurgery remains at the forefront of surgical innovation.

6. SUMMARY

In summary, this thesis investigates the advancements and clinical applications of reconstructive microsurgery, a field that has significantly improved outcomes for patients requiring complex reconstructive procedures. Through detailed analysis, the study highlights the evolution of microsurgical techniques, particularly focusing on microvascular and microneural procedures, which have enabled the successful repair and restoration of intricate anatomical structures.

Key clinical applications such as free tissue transfers are explored, showcasing their essential role in addressing extensive defects and restoring both function and aesthetics. The thesis also addresses the challenges faced by the field, including the need for extensive training, high costs of equipment, and the complexity of postoperative care, while emphasizing the importance of multidisciplinary collaboration in patient recovery.

Recent technological advancements, like super-microsurgery, are examined for their potential to push the boundaries of what is achievable in the field. The study suggests that continuous research and innovation are crucial for overcoming current limitations and expanding the scope of reconstructive microsurgery.

Lastly, reconstructive microsurgery has become a cornerstone of modern surgical practice, offering innovative solutions for complex reconstructive challenges. The future of this field is promising, with ongoing advancements expected to further enhance patient outcomes and quality of life.

Key words: Free flap, microvascular surgery, microneural surgery, reconstructive microsurgery, replantation

7. REFERENCES

1. Tyagi SA, Kumar SA. Microsurgery: An important tool for reconstructive surgery-A Review. *Int J Pharma Bio Sci.* 2010;1:1.
2. F Charles Brunnicardi, Dunn DL, Hunter JG, Andersen DK, Billiar TR. Schwartz's principles of surgery / F. Charles Brunnicardi, Dana K. Andersen, Timothy R. Billiar, David L. Dunn, and John G. Hunter. New York McGraw-Hill Education; 2015.
3. Microsurgery [Internet]. [cited 2024 May 21]. Available from: <https://www.plasticsurgery.org/reconstructive-procedures/microsurgery>
4. Supermicrosurgery for the Treatment of Lymphedema [Internet]. Cleveland Clinic. [cited 2024 May 21]. Available from: <https://consultqd.clevelandclinic.org/supermicrosurgery-for-the-treatment-of-lymphedema>
5. O'Brien BM, Morrison WA. Reconstructive microsurgery. Edinburgh, UK: Churchill Livingstone; 1987.
6. Nikkhah D, Rawlins J, Pafitanis G. Core techniques in flap reconstructive microsurgery a stepwise guide. Cham, Switzerland: Springer International Publishing; 2023.
7. Mendez BM, Chiodo MV, Vandevender D, Patel PA. Heads-up 3D microscopy: An ergonomic and educational approach to Microsurgery. *Plastic and Reconstructive Surgery - Global Open.* 2016 May;4(5). doi:10.1097/gox.0000000000000727
8. Banowsky LH. Basic microvascular techniques and Principles. *Urology.* 1984 May;23(5):495–503. doi:10.1016/s0090-4295(84)80013-8
9. MacDonald JD. Learning to perform microvascular anastomosis. *Skull Base.* 2005 Aug 15;15(03):229–40. doi:10.1055/s-2005-872598
10. Khachatryan A, Tevosyan A, Novoselskiy D, Arakelyan G, Yushkevich A, Nazarian DN. *Microsurgery Manual for medical students and residents.* S.L., Switzerland: Springer International Publishing; 2021.
11. Tamai S, Usui M, Yoshizu T. *Experimental and clinical reconstructive microsurgery.* 1st ed. Tokyo, Japan: Springer; 2003.
12. Lahiri A, Sebastin SJ, Khadijah S, Lee EY, Chong AK [Internet]. National University Hospital Singapore; [cited 2024 May 24]. Available from: https://www.nuh.com.sg/our-services/Specialties/Orthopaedics-Reconstructive-Microsurgery/Hand%20and%20Reconstructive%20Microsurgery/Documents/microsurgical_training_manual_NUH.pdf

13. Buntic R. MICROSURGEON.ORG [Internet]. [cited 2024 May 26]. Available from: <https://www.microsurgeon.org/replantation>
14. Meyer VE. Upper Extremity replantation – A Review. *European Surgery*. 2003 Aug;35(4):167–73. doi:10.1007/s10353-003-0001-3
15. Lin P-Y, Jeng S-F, Lin T-S, Hsieh C-H. Upper limb replantation. *Trauma*. 2012 May 31;14(4):313–26. doi:10.1177/1460408612440648
16. Kutz JE, Jupiter JB, Tsai T-M. Lower limb replantation: A report of nine cases. *Foot & Ankle*. 1983 Jan;3(4):197–202. doi:10.1177/107110078300300403
17. Tsuge K, Caroli A. 25 Microchirurgia. In: *Atlante di Chirurgia della Mano*. Milano, Italy: McGraw-Hill libri Italiani; 1988. p. 531–53.
18. Acland RD. *Microsurgery Practice Manual*. St. Louis: Mosby; 1980.
19. Lister G, Godina M. Marko Godina - a thesis. Ljubljana, Slovenija: PREŠERNOVA DRUŽBA; 1991.
20. Zhang L. Digit amputation [Internet]. U.S. National Library of Medicine; 2023 [cited 2024 May 27]. Available from: <https://www.ncbi.nlm.nih.gov/books/NBK538153/>
21. Scaglioni MF, Rittirsch D, Giovanoli P. Reconstruction of the heel, middle foot sole, and plantar forefoot with the medial plantar artery perforator flap: Clinical experience with 28 cases. *Plastic & Reconstructive Surgery*. 2018 Jan;141(1):200–8. doi:10.1097/prs.0000000000003975
22. del Piñal F, Klausmeyer M, Moraleda E, de Piero GH, Rúas JS, Klich M. Foot web free flaps for single-stage reconstruction of hand webs. *The Journal of Hand Surgery*. 2015 Jun;40(6):1152–60. doi:10.1016/j.jhsa.2015.02.001
23. Starnoni M, Benanti E, Acciaro AL, De Santis G. Upper limb traumatic injuries: A concise overview of reconstructive options. *Annals of Medicine & Surgery*. 2021 Jun;66. doi:10.1016/j.amsu.2021.102418
24. Valentin Georgescu A. Reconstructive microsurgery in Upper Limb Reconstruction: 30 years' experience of a single surgeon. *Journal of Hand Surgery (European Volume)*. 2020 Apr 20;45(8):787–97. doi:10.1177/1753193420915398
25. Heller L, Levin LS. Lower Extremity Microsurgical Reconstruction. *Plastic and Reconstructive Surgery*. 2001 Sept;108(4):1042. doi:10.1097/00006534-200109150-00037
26. Engel H, Lin C-H, Wei F-C. Role of microsurgery in lower extremity reconstruction. *Plastic and Reconstructive Surgery*. 2011 Jan;127. doi:10.1097/prs.0b013e3182008e12
27. Avraham T, Clavin N, Mehrara BJ. Microsurgical Breast Reconstruction. *The Cancer Journal*. 2008 Jul;14(4):241–7. doi:10.1097/ppo.0b013e31817fb7e3

28. Onoda S, Masahito K. Microsurgery for head and neck reconstruction. *Journal of Craniofacial Surgery*. 2020 Mar 27;31(5):1441–4. doi:10.1097/scs.00000000000006361
29. Park H, Jeong SS, Oh TS. Masseter nerve-based facial palsy reconstruction. *Archives of Craniofacial Surgery*. 2020 Dec 20;21(6):337–44. doi:10.7181/acfs.2020.00682
30. Owen ER. Microsurgical vasovasostomy: A reliable vasectomy reversal. *Journal of Urology*. 2002 Feb;167(2 Part 2):1205–1205. doi:10.1016/s0022-5347(02)80388-3
31. Garibyan H, Hazebroek FW, Schulkes JA, Molenaar JC, Dabhoiwala NF. Microvascular surgical orchiopexy in the treatment of high-lying undescended testes. *British Journal of Urology*. 1984 Jun;56(3):326–9. doi:10.1111/j.1464-410x.1984.tb05398.x
32. Wallach EE, Winston RML. Microsurgery of the fallopian tube: From fantasy to Reality. *Fertility and Sterility*. 1980 Dec;34(6):521–30. doi:10.1016/s0015-0282(16)45188-5
33. Hong JP, Song S, Suh HS. Supermicrosurgery: Principles and applications. *Journal of Surgical Oncology*. 2018 Sept 27;118(5):832–9. doi:10.1002/jso.25243
34. Badash I, Gould DJ, Patel KM. Supermicrosurgery: History, applications, training and the future. *Frontiers in Surgery*. 2018 Mar 21;5. doi:10.3389/fsurg.2018.00023
35. van Mulken TJ, Qiu SS, Jonis Y, Profar JJ, Blokhuis TJ, Geurts J, et al. First-in-human integrated use of a dedicated microsurgical robot with a 4K 3D EXOSCOPE: The Future of Microsurgery. *Life*. 2023 Mar 3;13(3):692. doi:10.3390/life13030692
36. Cau R. Design and realization of a master-slave system for reconstructive microsurgery. 2014 Jan 1; doi:10.6100/IR763107
37. Visconti G, Hayashi A, Hong JP. The new imaging techniques in reconstructive microsurgery: A new revolution in Perforator flaps and lymphatic surgery. *Archives of Plastic Surgery*. 2022 Jul;49(04):471–2. doi:10.1055/s-0042-1751099
38. Blank B, Cai A. Imaging in reconstructive microsurgery – current standards and latest trends. *Innovative Surgical Sciences*. 2023 Dec 1;8(4):227–30. doi:10.1515/iss-2023-0040

FIGURES:

1. Themes U. Microsurgery and flaps [Internet]. 2016 [cited 2024 May 24]. Available from: <https://plasticsurgerykey.com/microsurgery-and-flaps/>
2. Boyd KU, Fox IK, Mackinnon SE. Nerve transfers [Internet]. 2016 [cited 2024 May 25]. Available from: <https://plasticsurgerykey.com/nerve-transfers/>
3. Goekjian S, Gallo L, Thoma A. Replantation [Internet]. 2023 [cited 2024 May 26]. Available from: <https://musculoskeletalkey.com/replantation-5/>

4. Themes U. Defect closure after lesion excision of the face [Internet]. 2017 [cited 2024 May 28]. Available from: <https://aneskey.com/defect-closure-after-lesion-excision-of-the-face/>

TABLES:

1& 2 Tamai S, Usui M, Yoshizu T. Experimental and clinical reconstructive microsurgery. 1st ed. Tokyo, Japan: Springer; 2003.

8. CV

Sara Cvrtak was born in Izola, Slovenia, on June 11, 1998. She began her education in 2004, attending primary school for nine years. In 2013, she enrolled in Gymnasium Koper, where she studied for four years. After graduating, Sara pursued an intensive English course, achieving a C1 level of proficiency.

In 2018, she began studying medicine at the Faculty of Medicine in Rijeka. Throughout her studies, Sara gained practical experience through various internships each summer. These included a family medicine internship at ZZ Zdravljenje Health Center, assisting in oral surgeries at Primadent Clinic with maxillofacial surgeons, an otorhinolaryngology internship at Dr. Jurasz University Hospital No. 1 in Poland, an anesthesiology and reanimation internship at the Orthopedic Clinic in Valdoltra, and a surgery internship at Aesthetic Clinic Fabijan in Kolomban.

She also educated herself further through additional programs, such as the 6th Osijek Student Congress: Precision Techniques and New Challenges - Mastering Plastic and Reconstructive Surgery, and the 8th Congress of Emergency Medicine at the Rijeka Medical Faculty.

Her immersion in diverse medical settings has deepened her understanding of various specialties and sharpened her skills, preparing her for the challenges and opportunities that lie ahead in her medical career.